

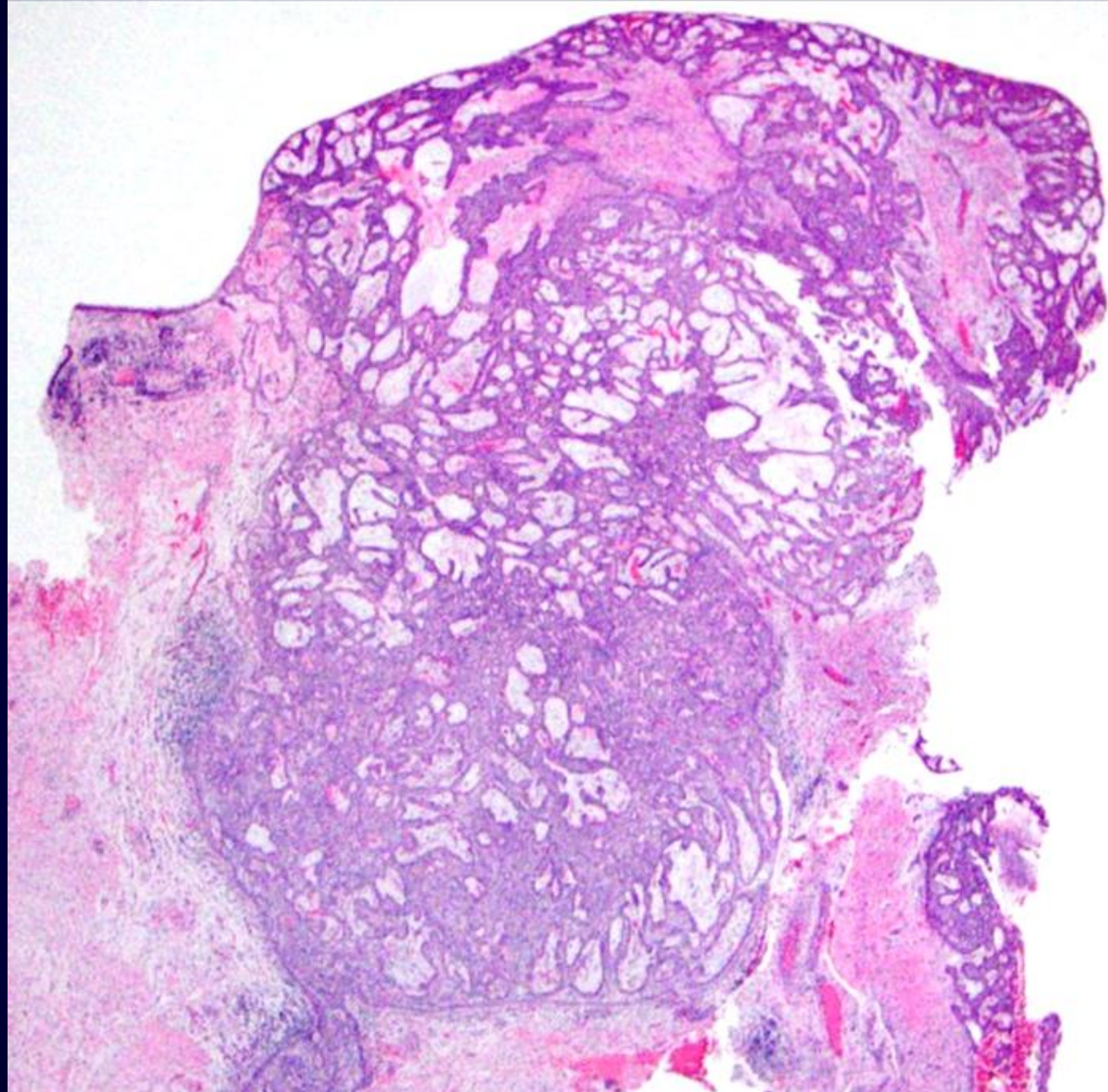
Oral Histopathology

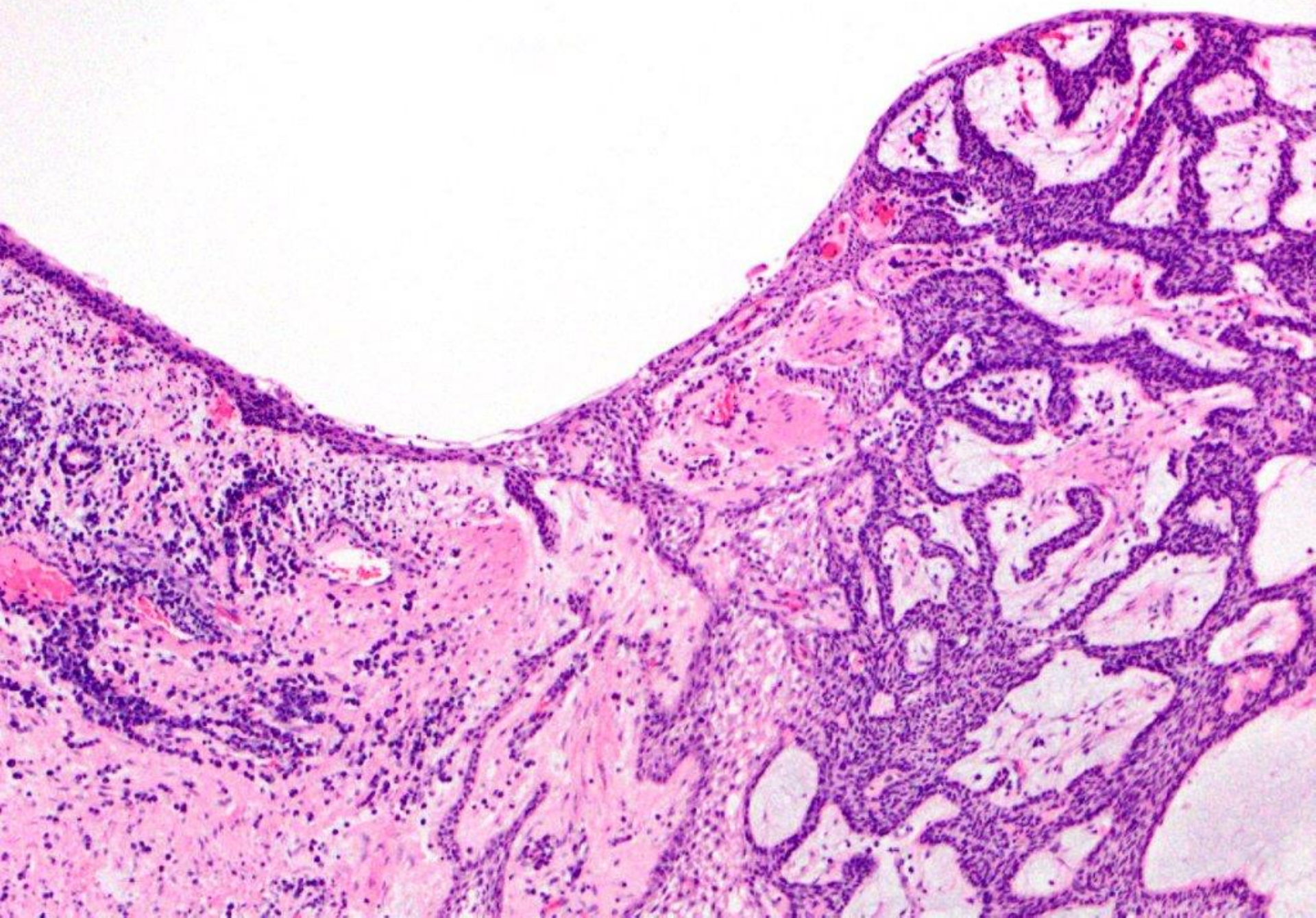
Series 15

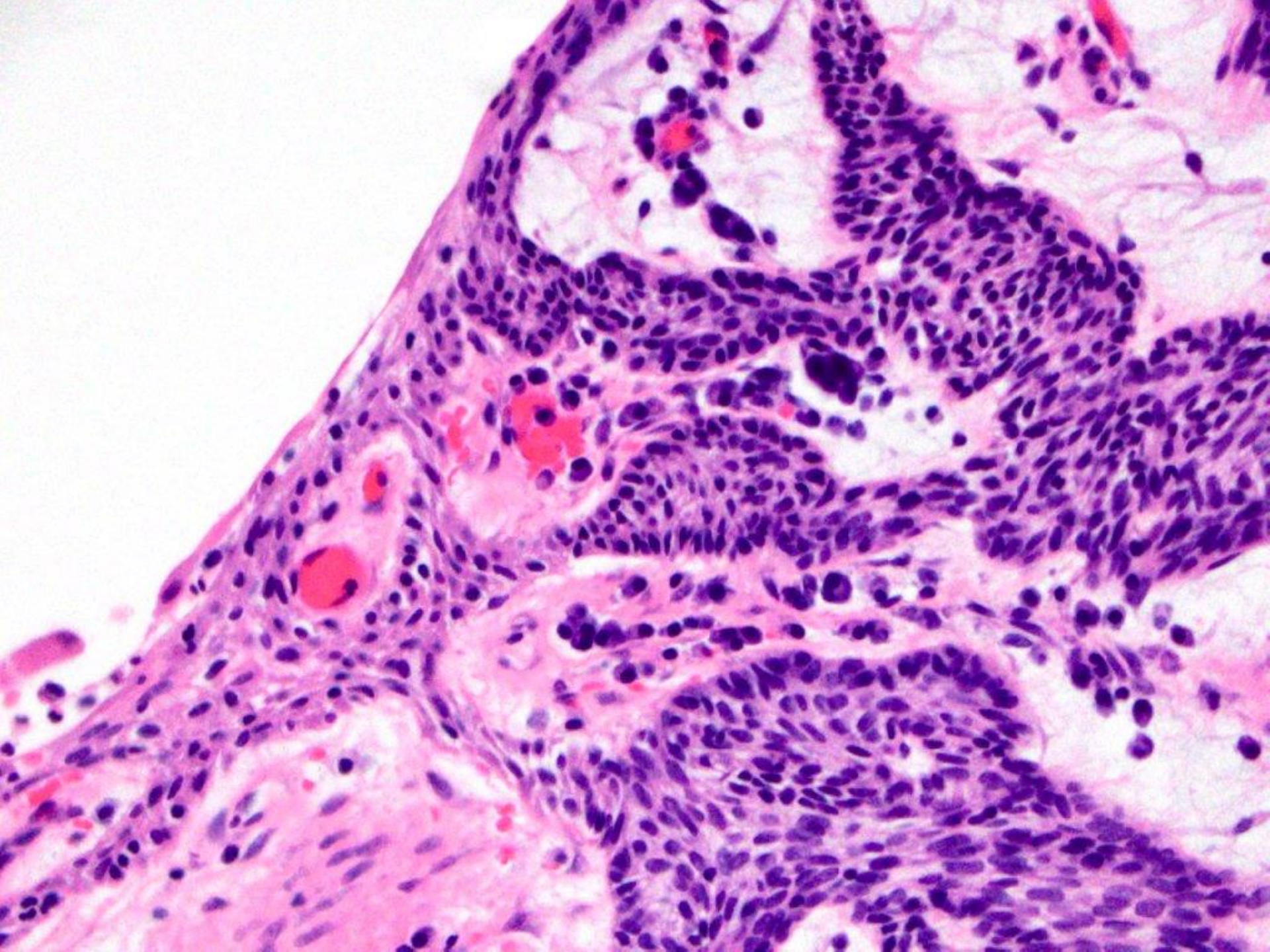
DAVID E. KLINGMAN, DMD

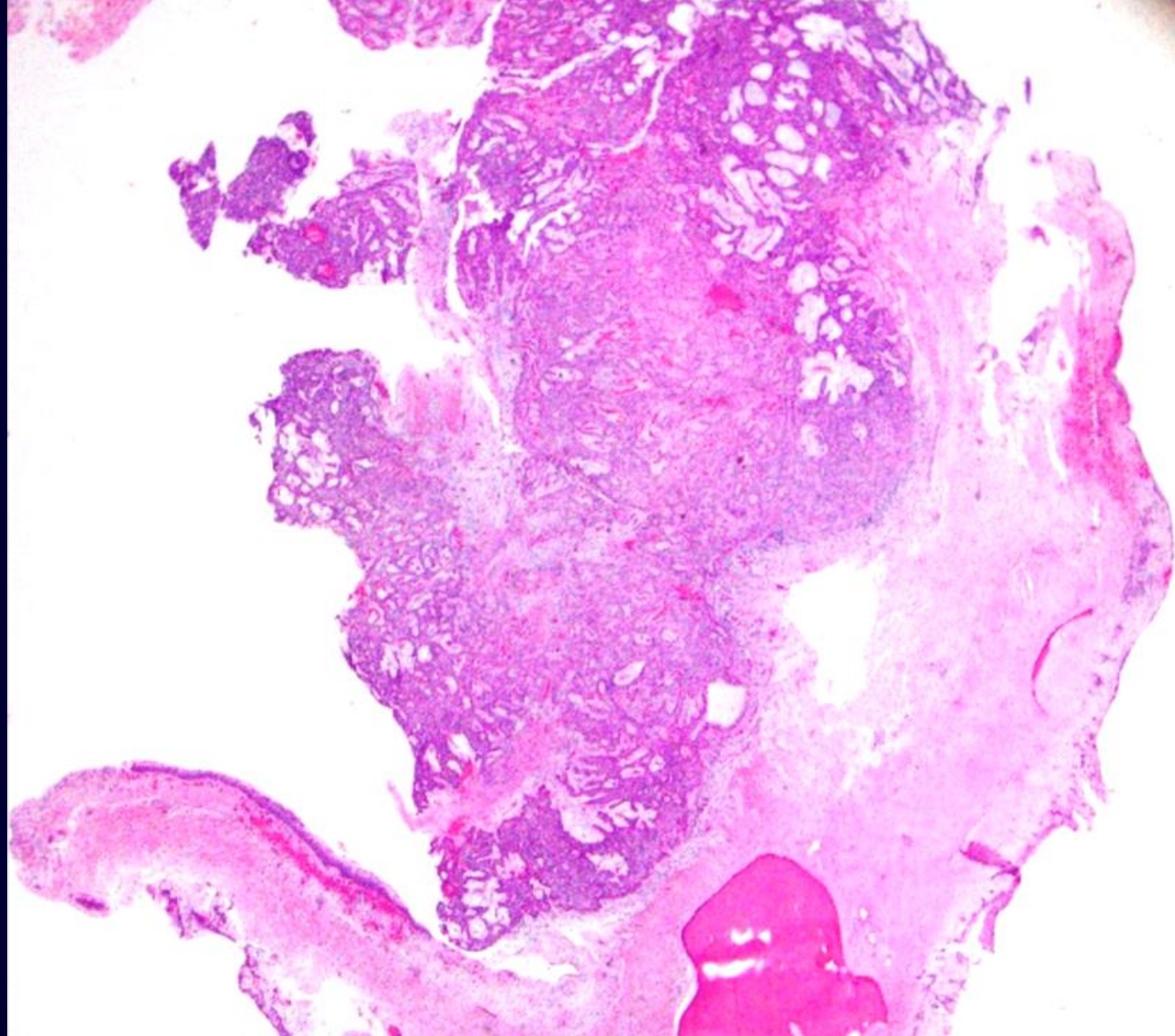
Diplomate, American Board of Oral and Maxillofacial Pathology

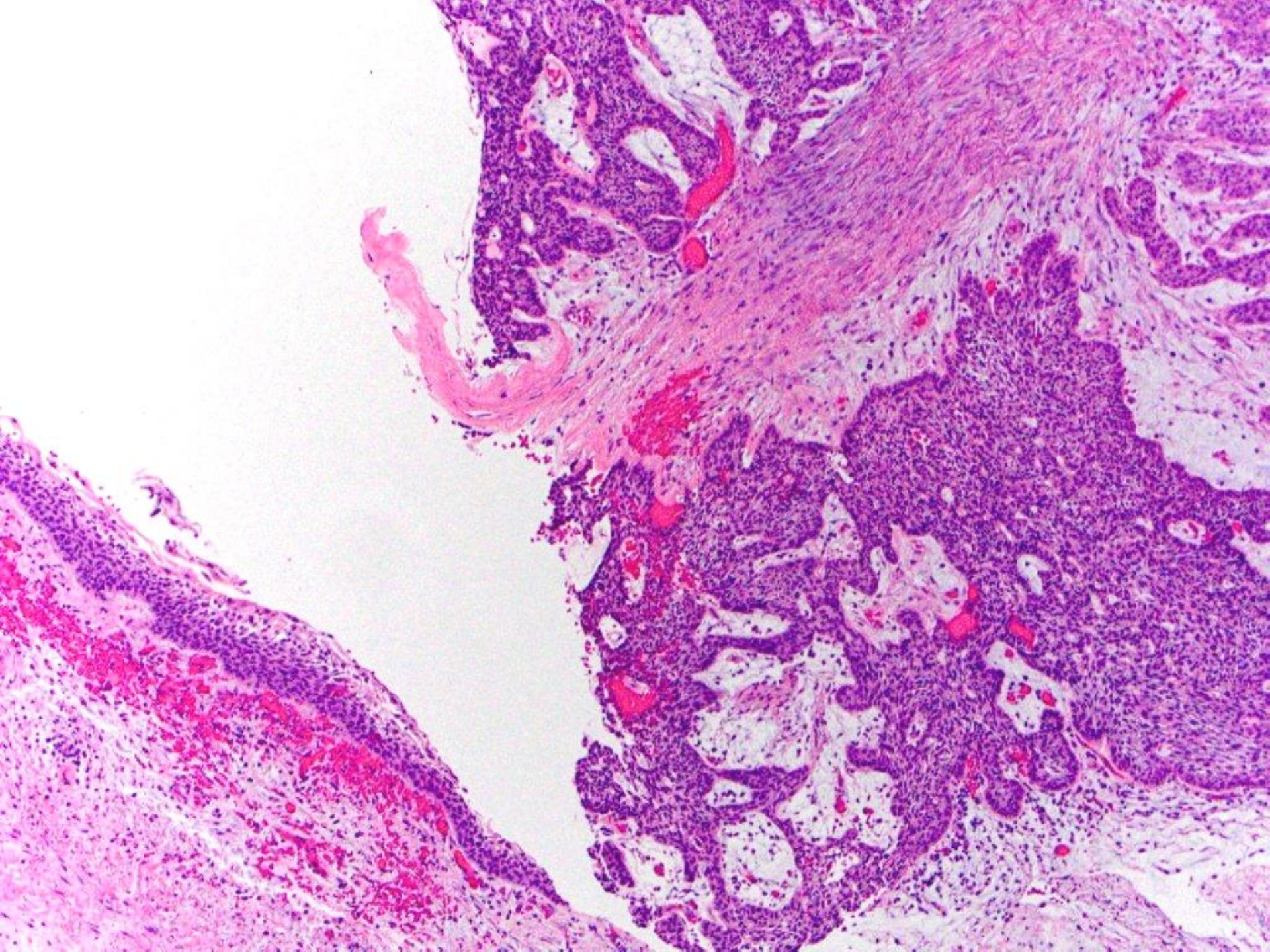
Diplomate, American Board of General Dentistry

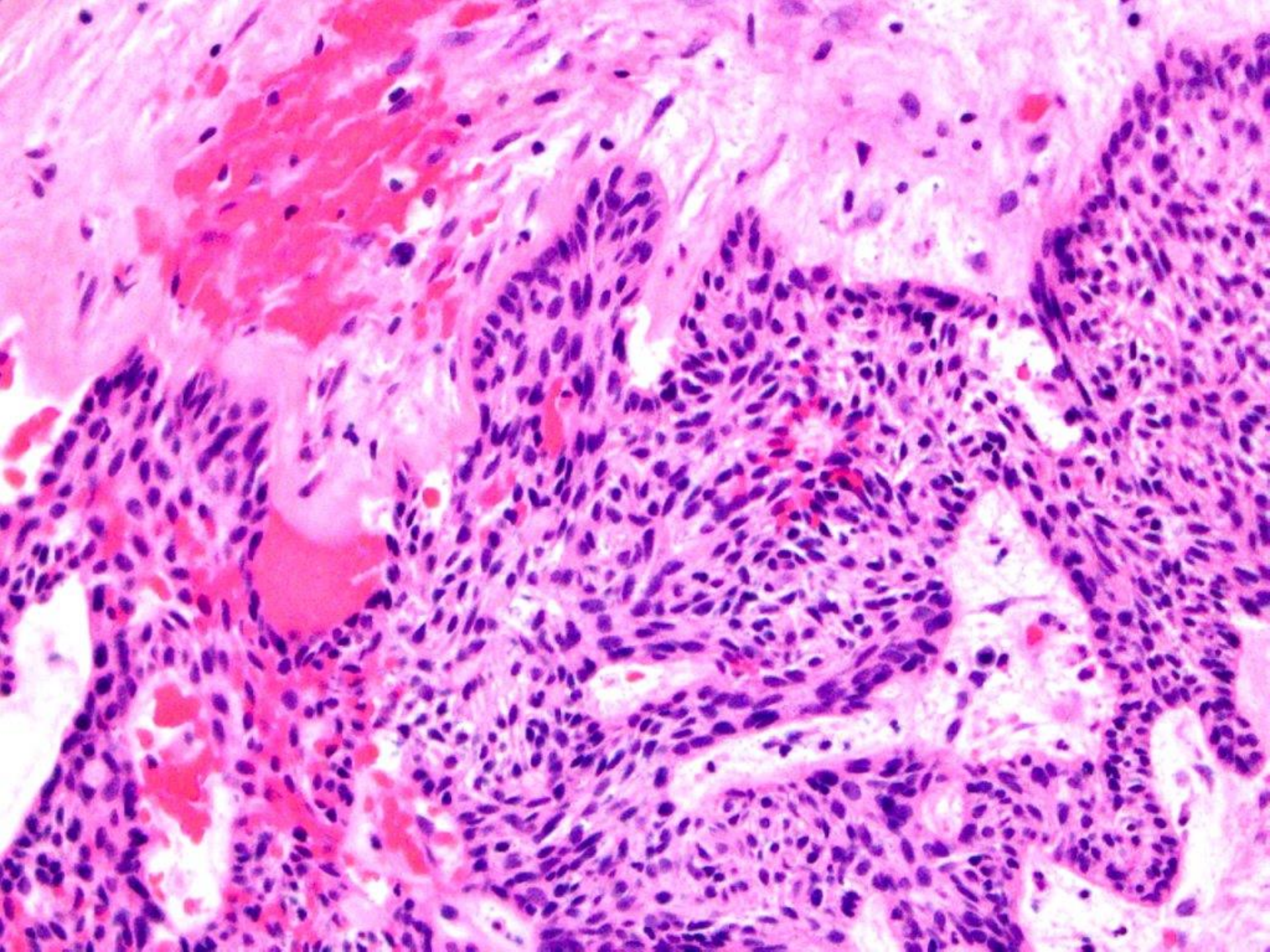


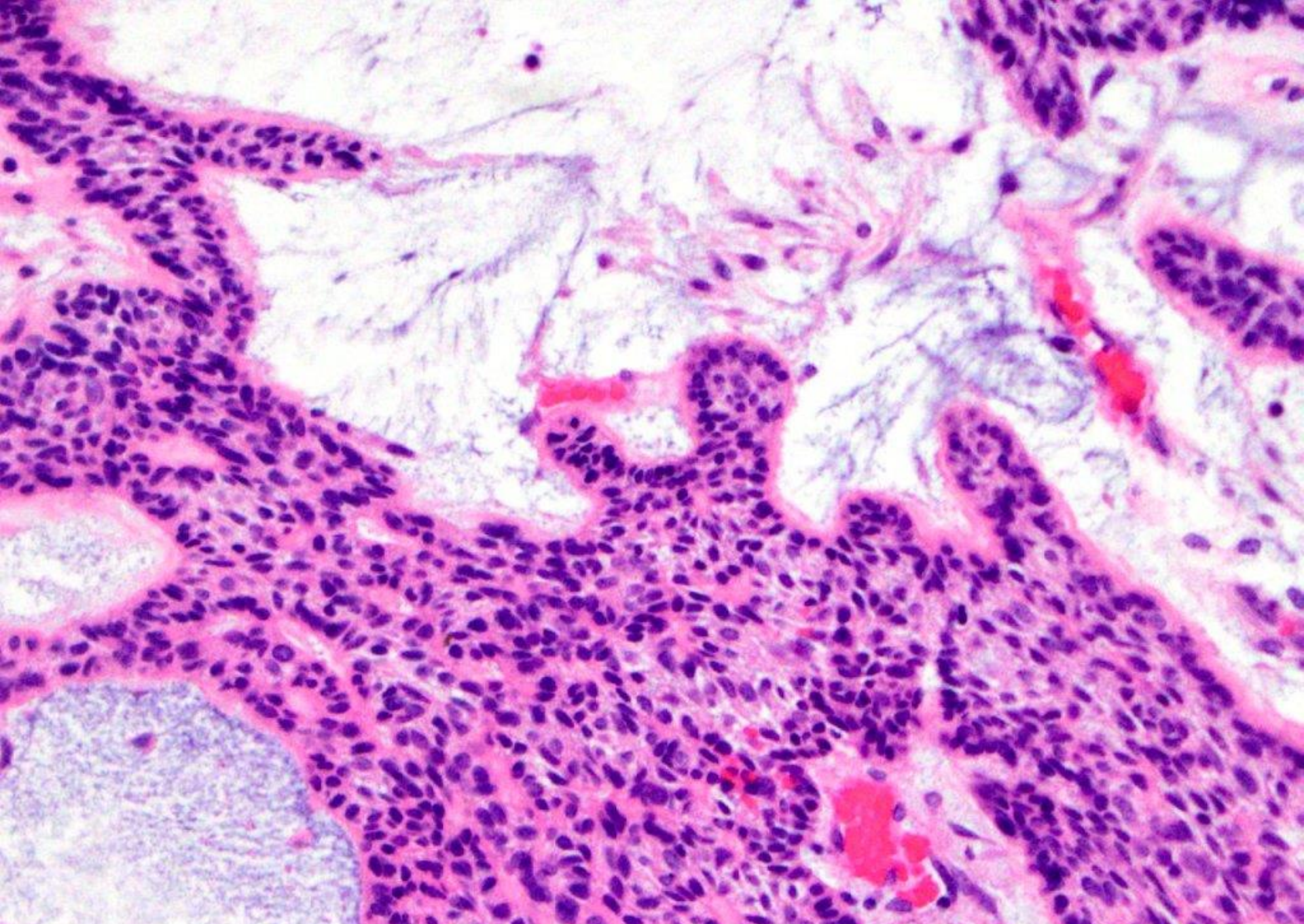




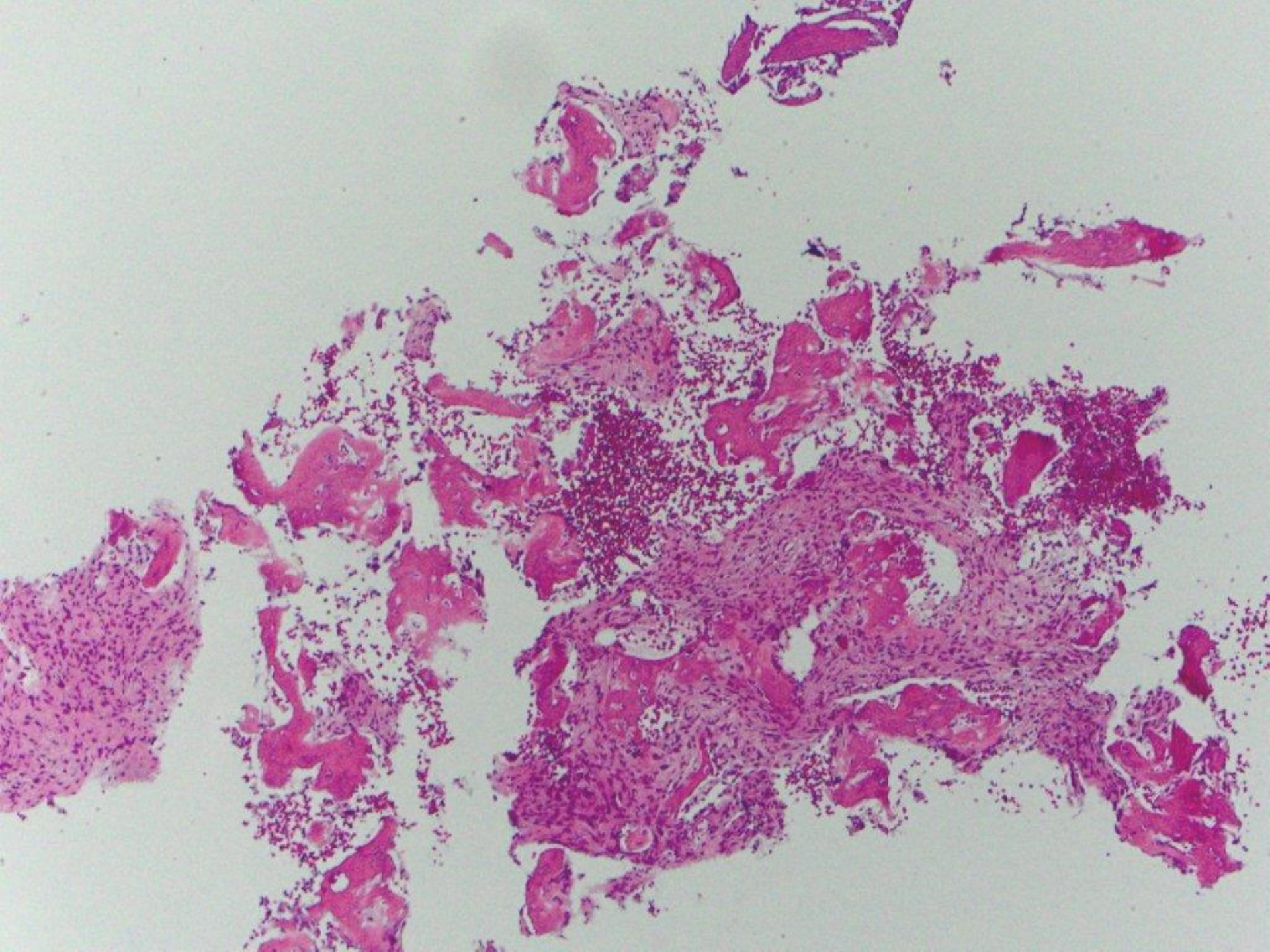


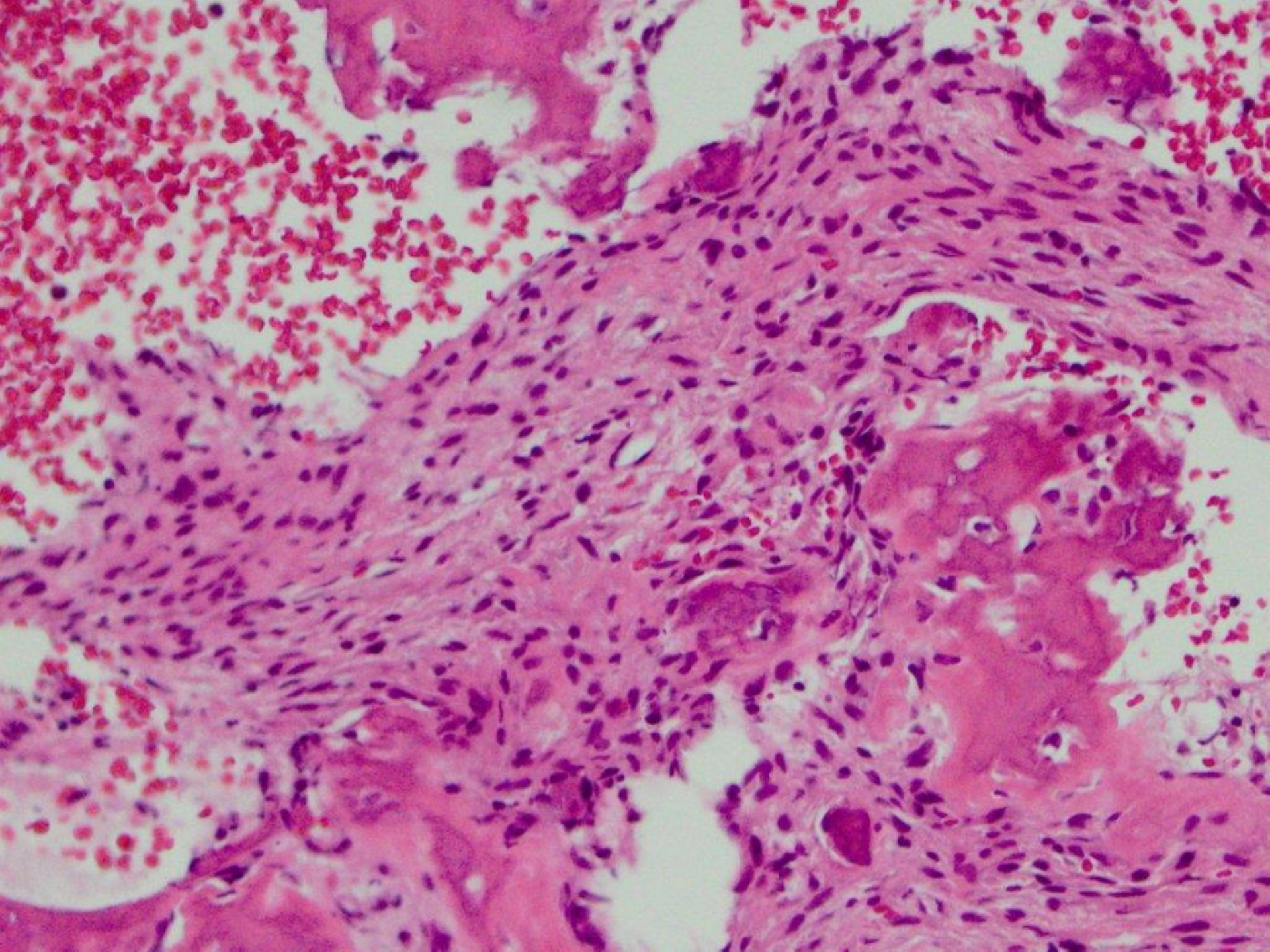


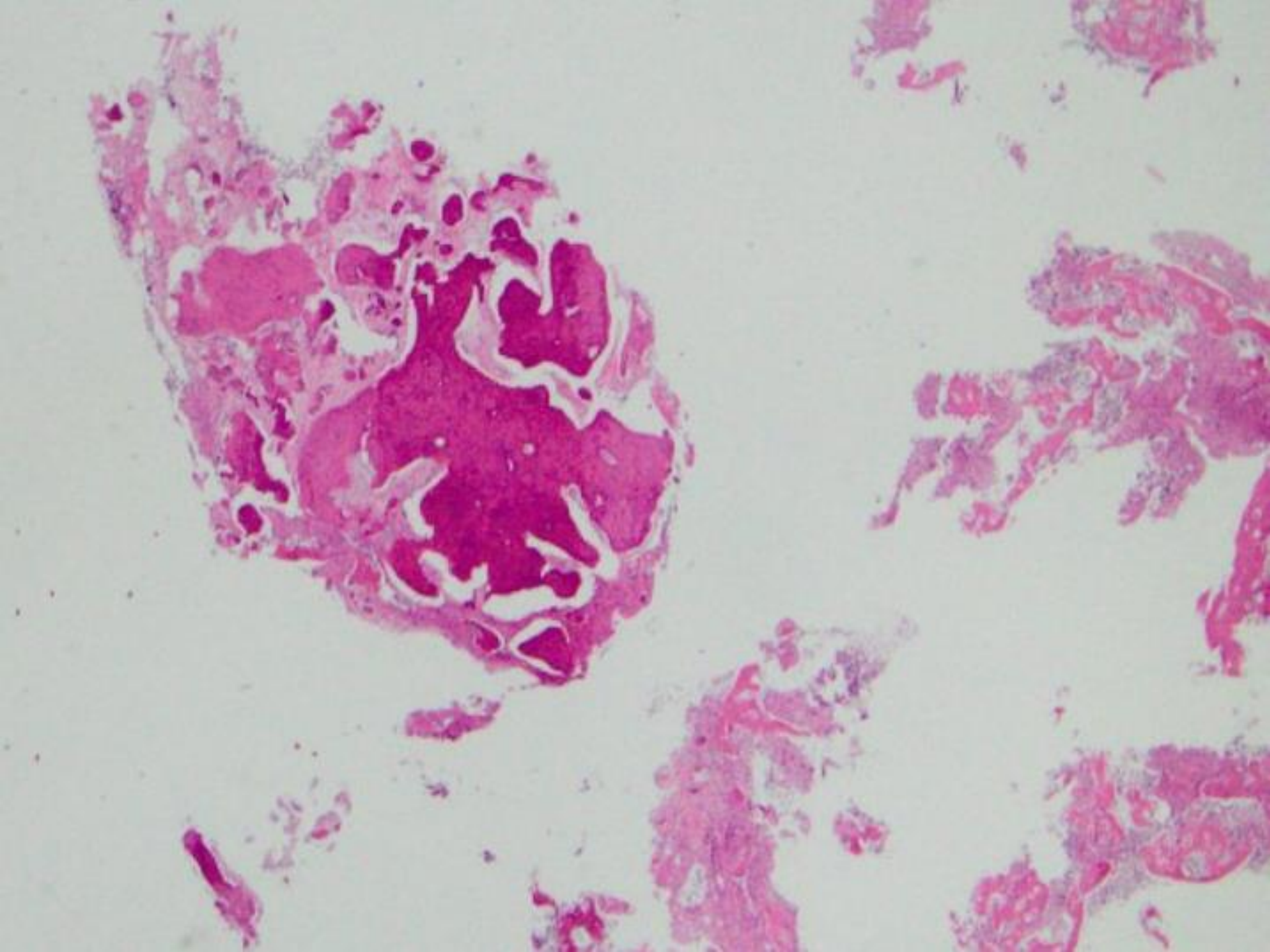


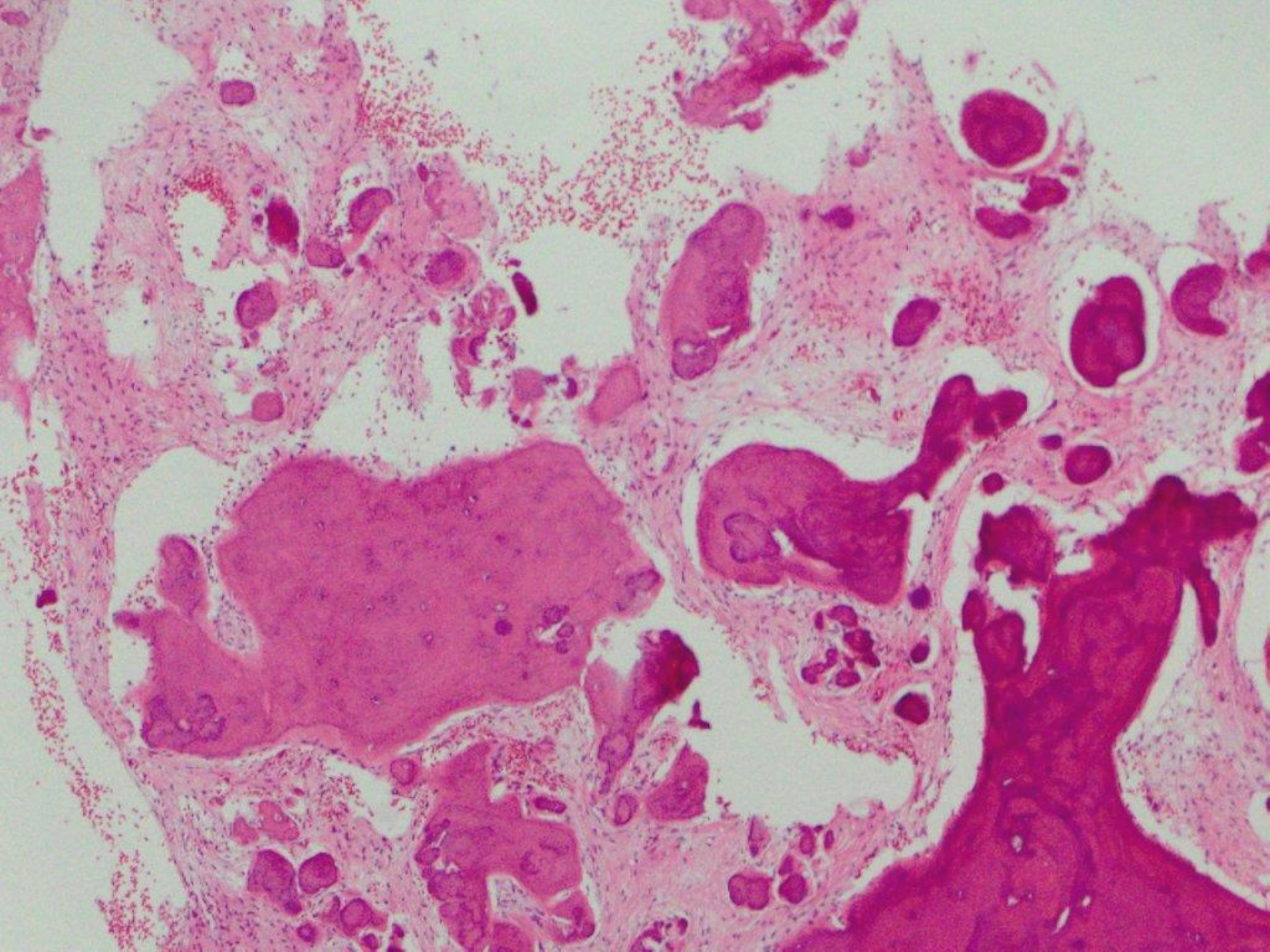


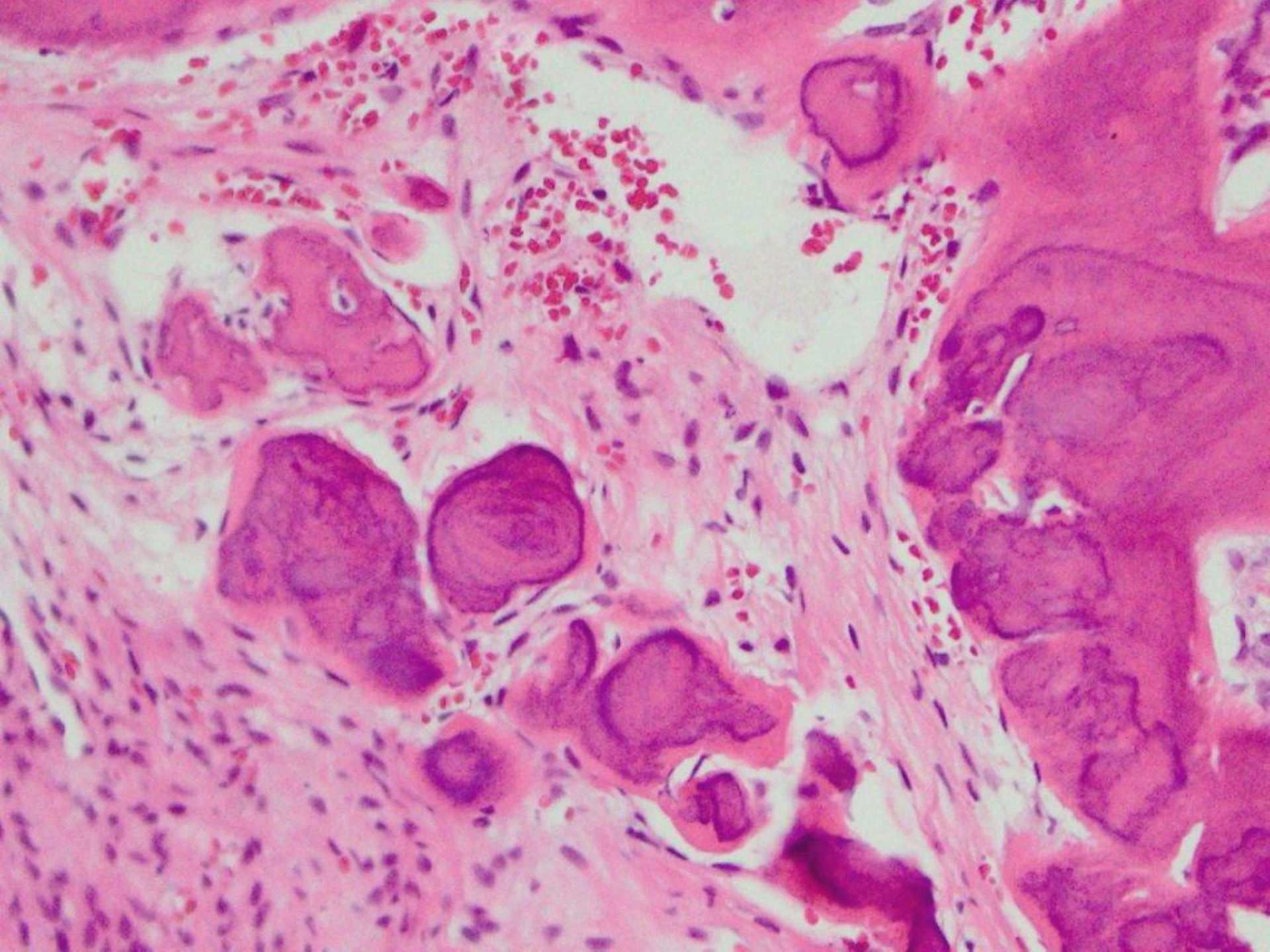
plexiform ameloblastoma arising from the lining of a cyst

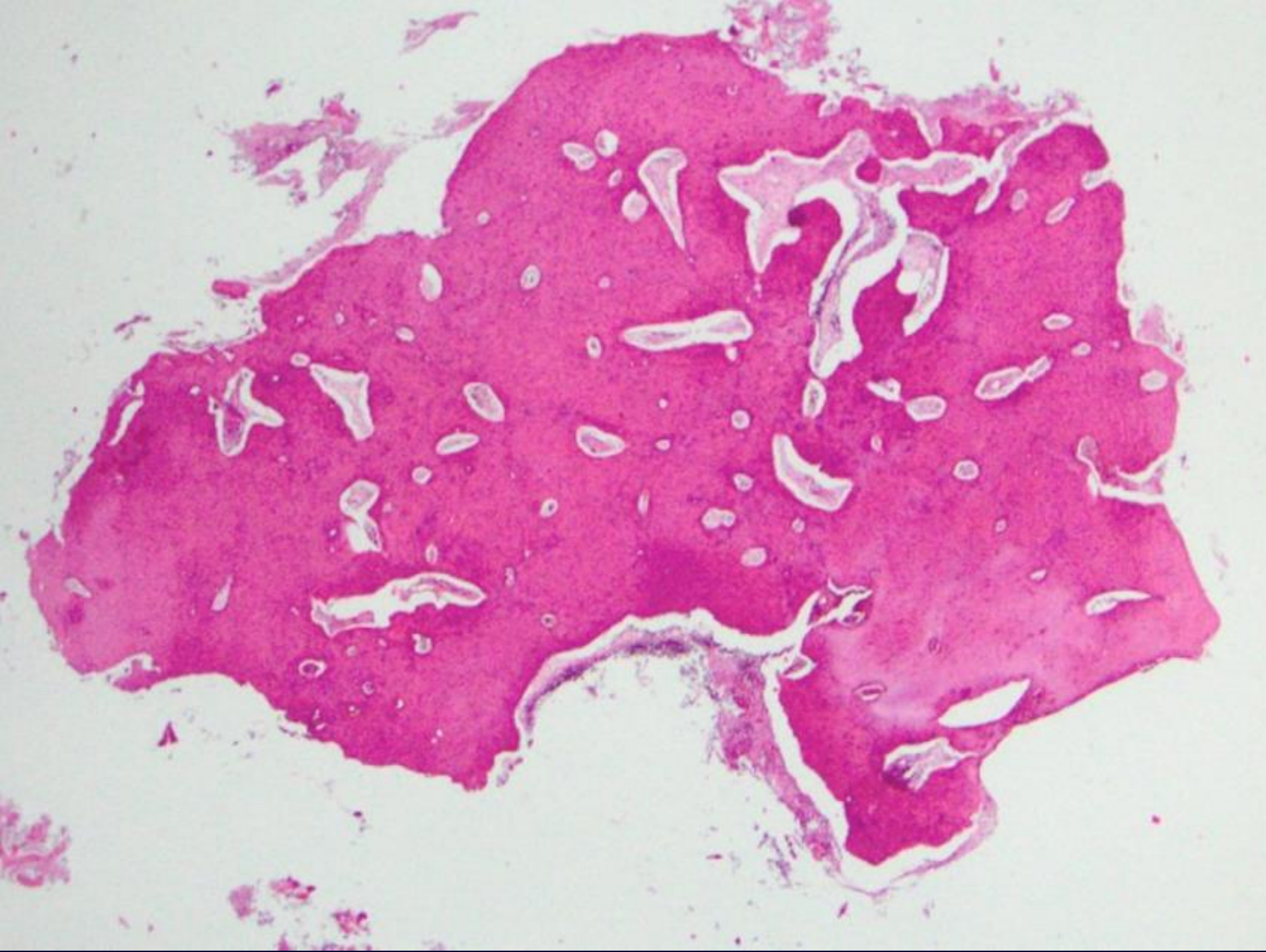


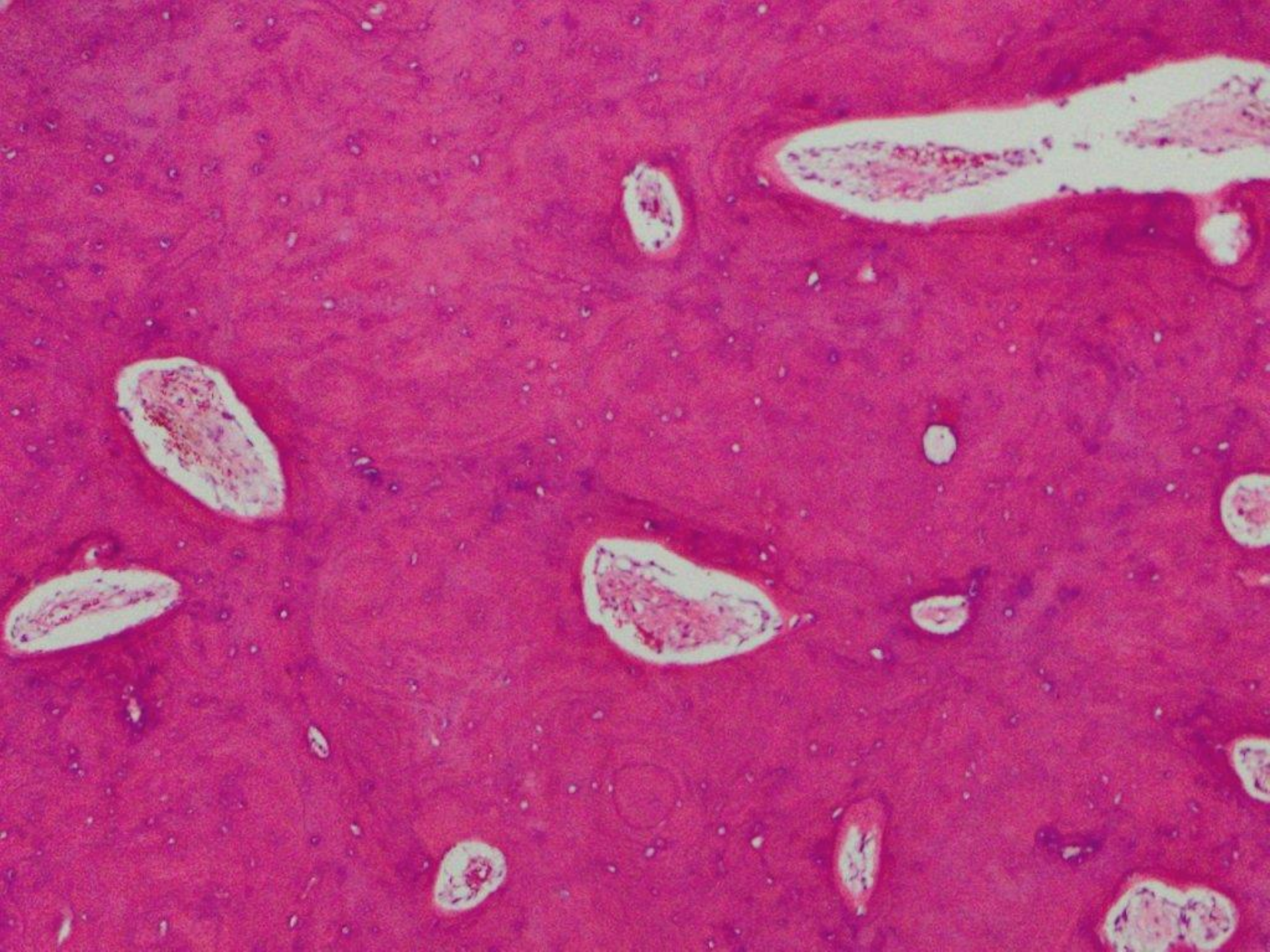


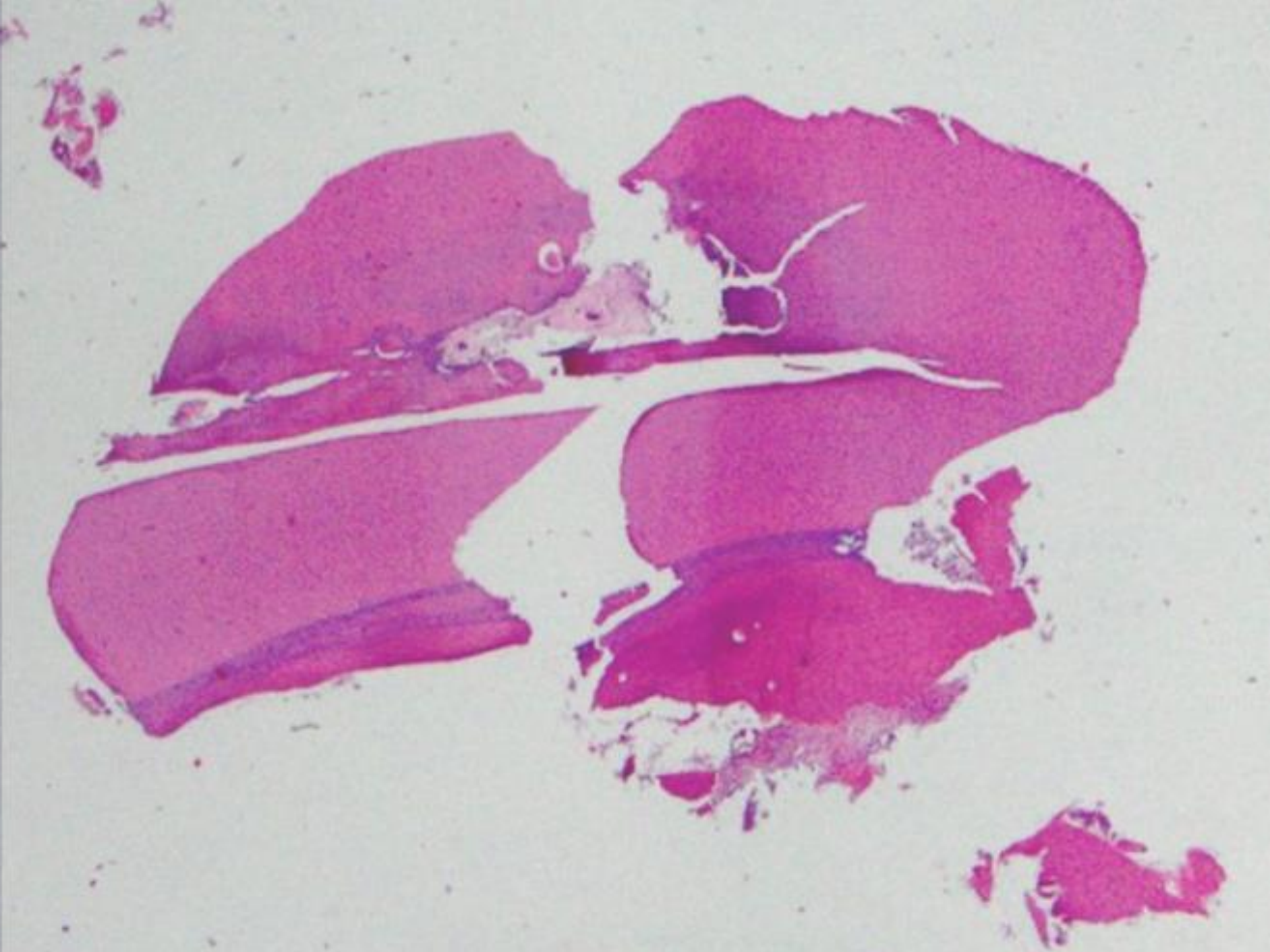






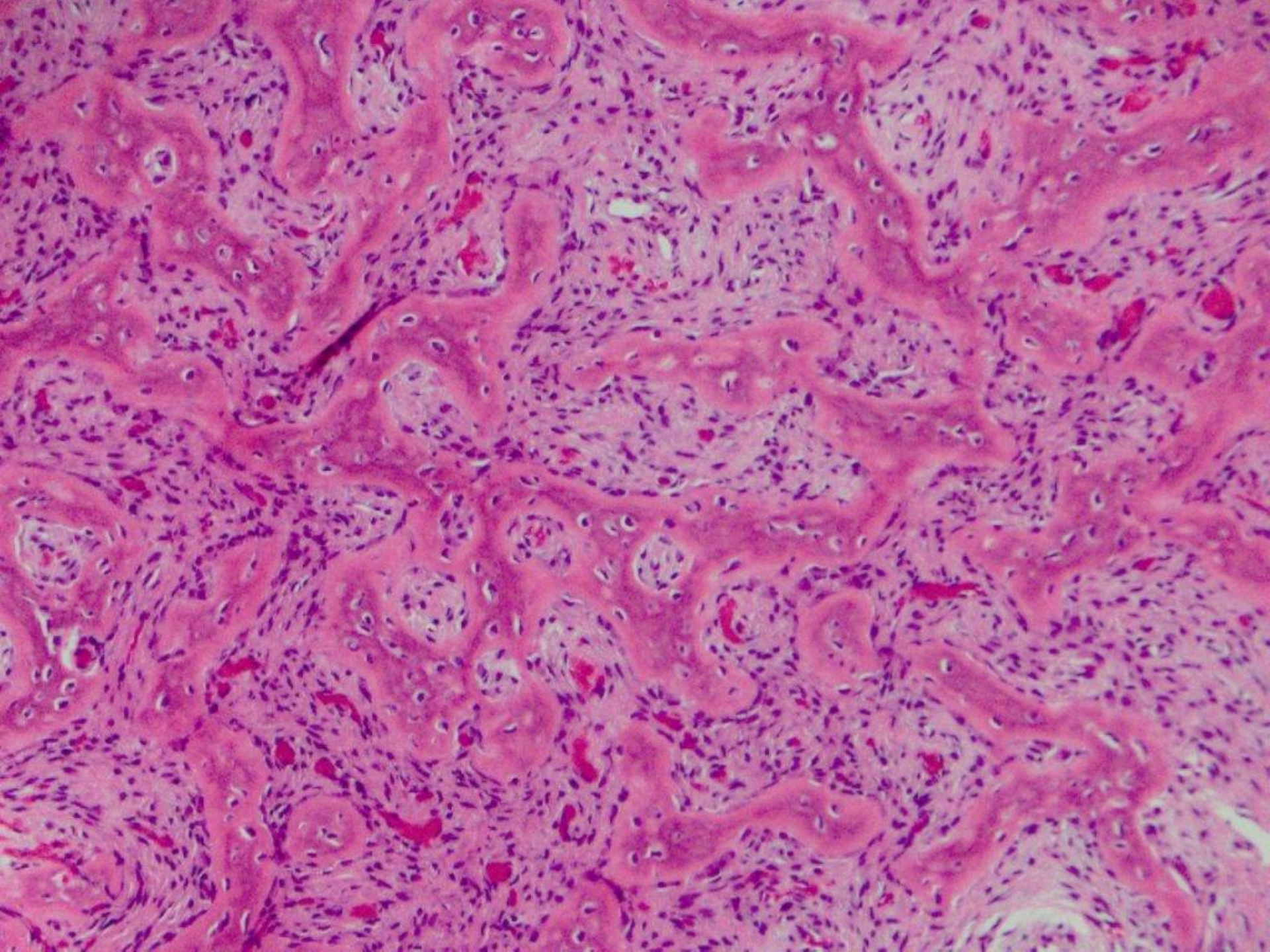


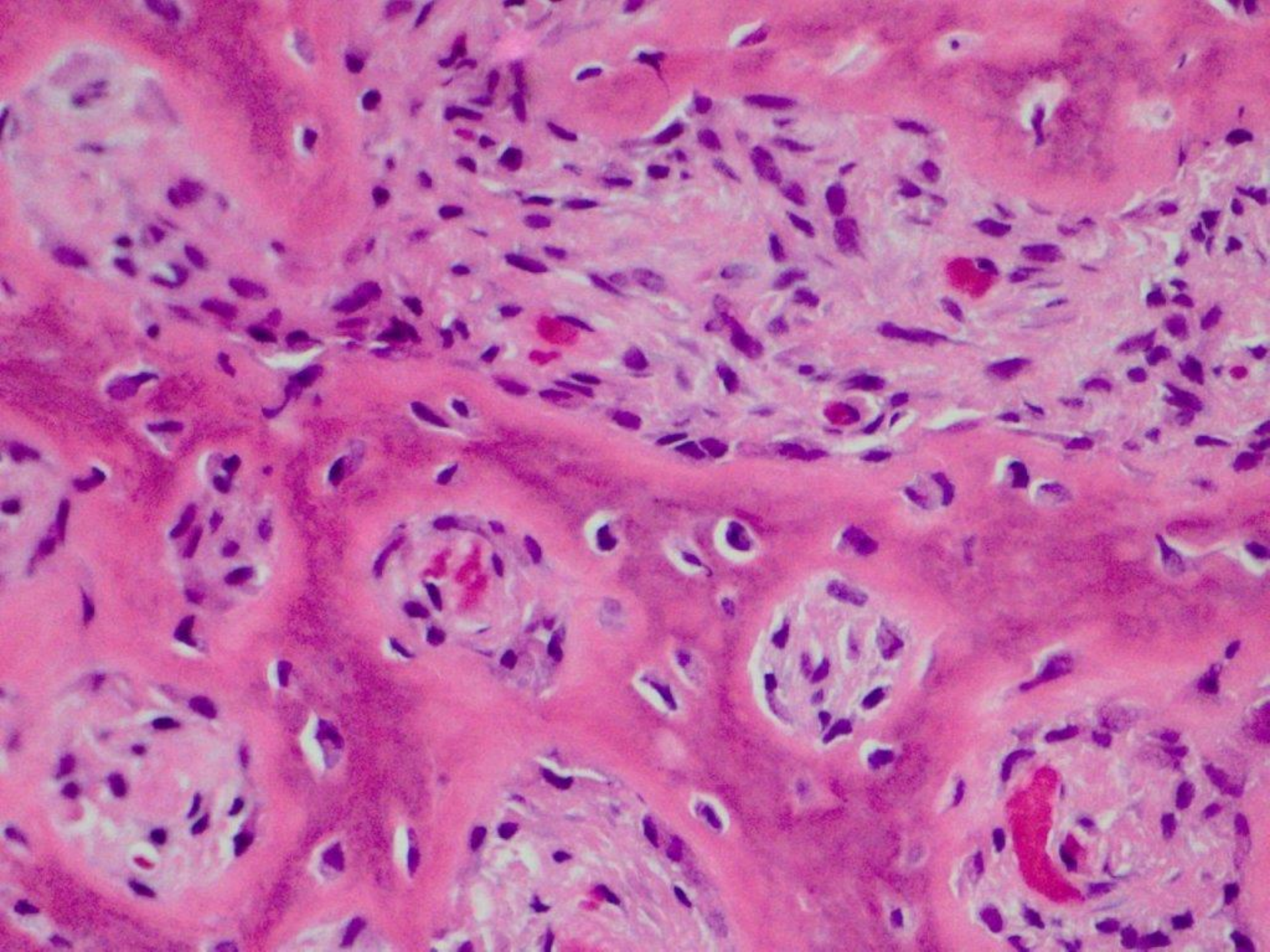


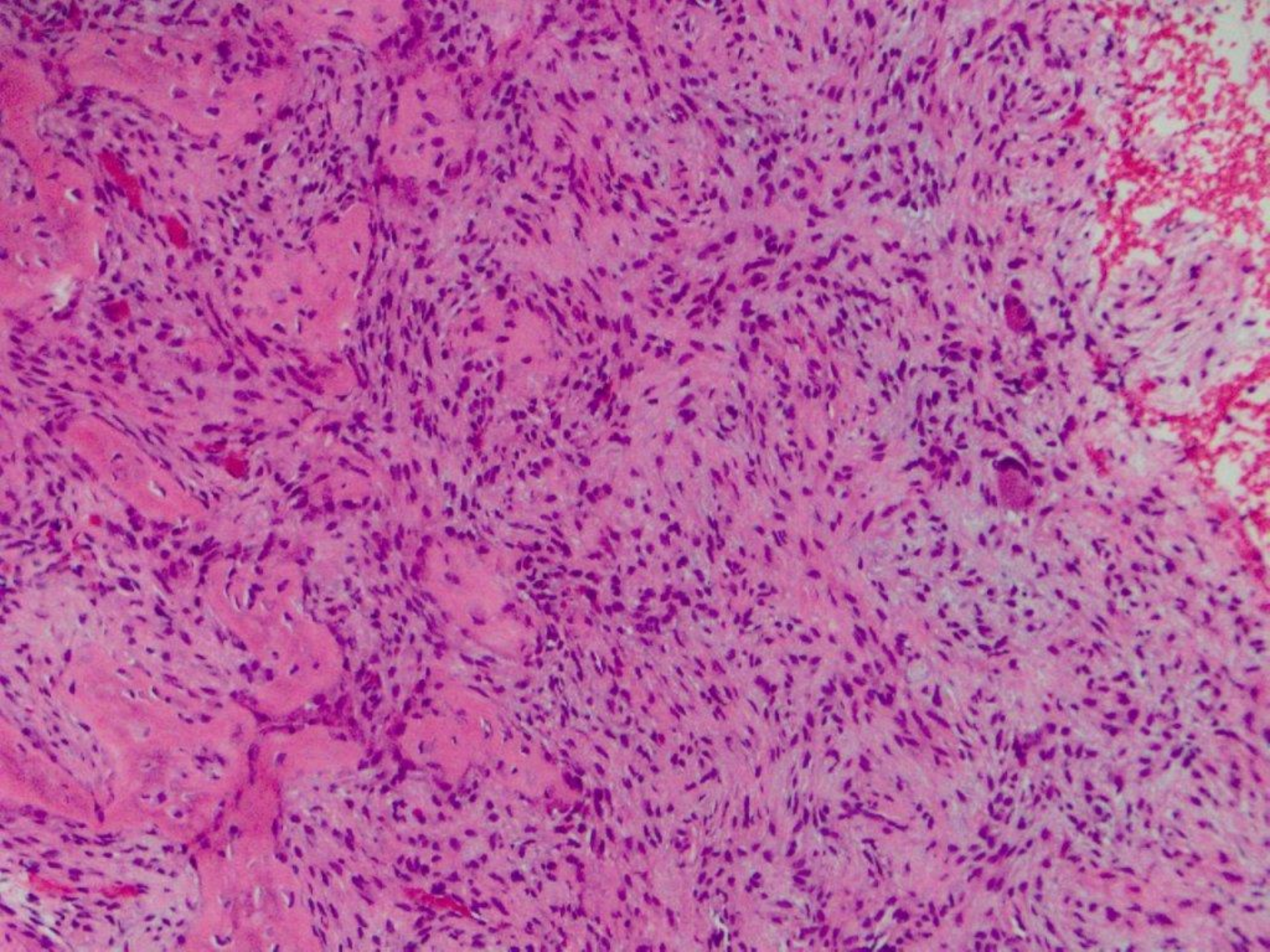


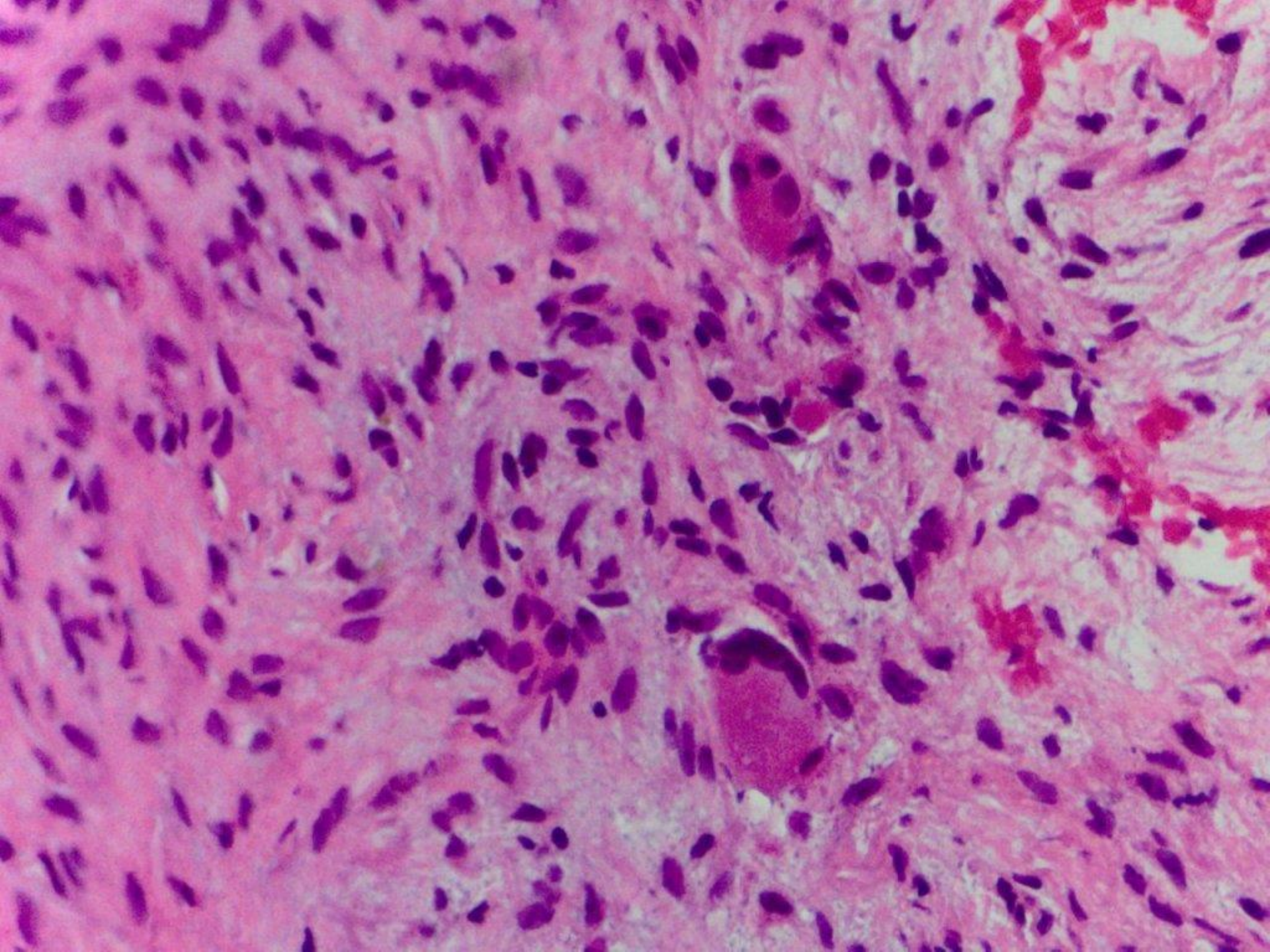


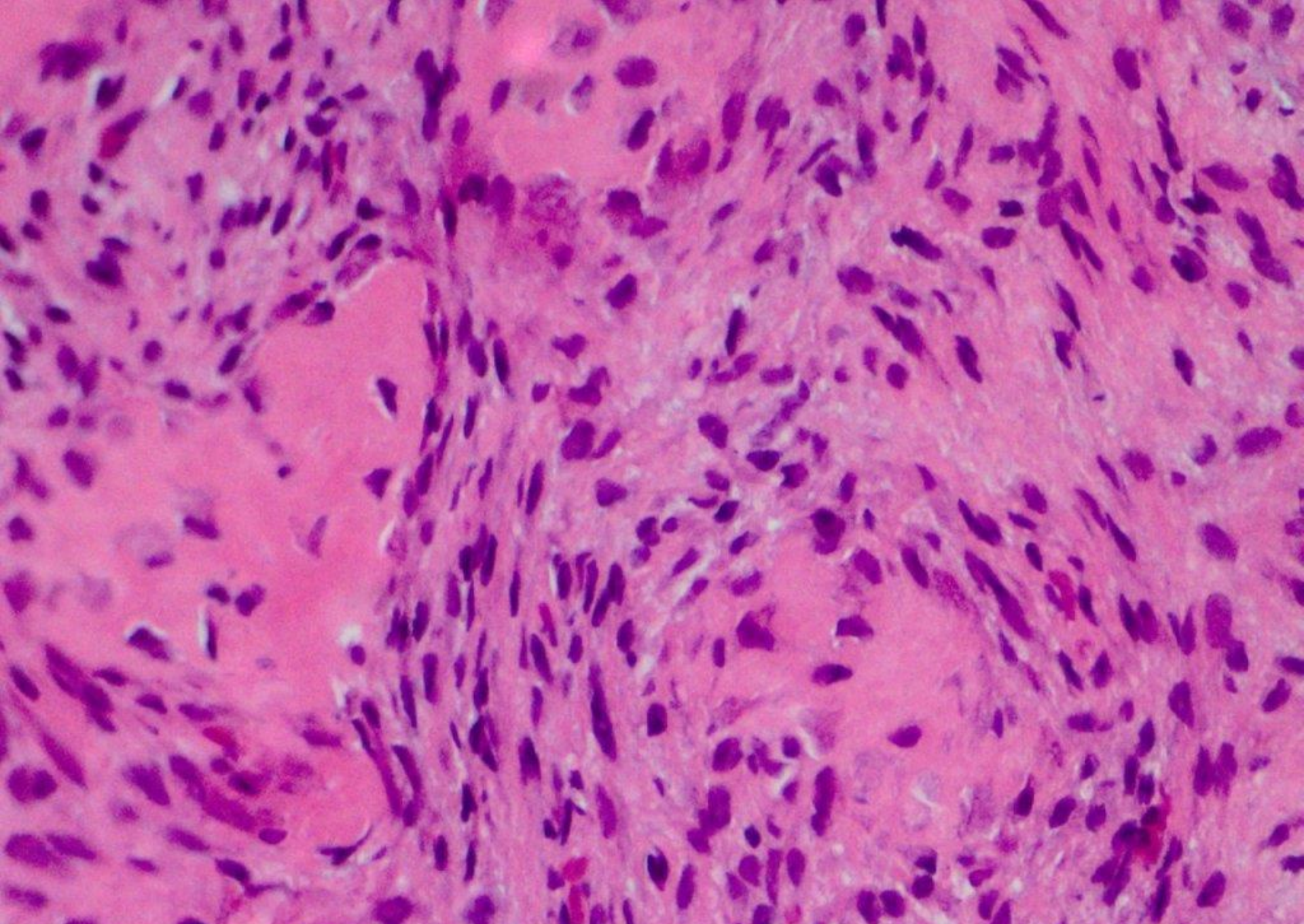
BFOL, consistent with cemento-osseous dysplasia (but radiographically attached to the root, suggestive of cementoblastoma)



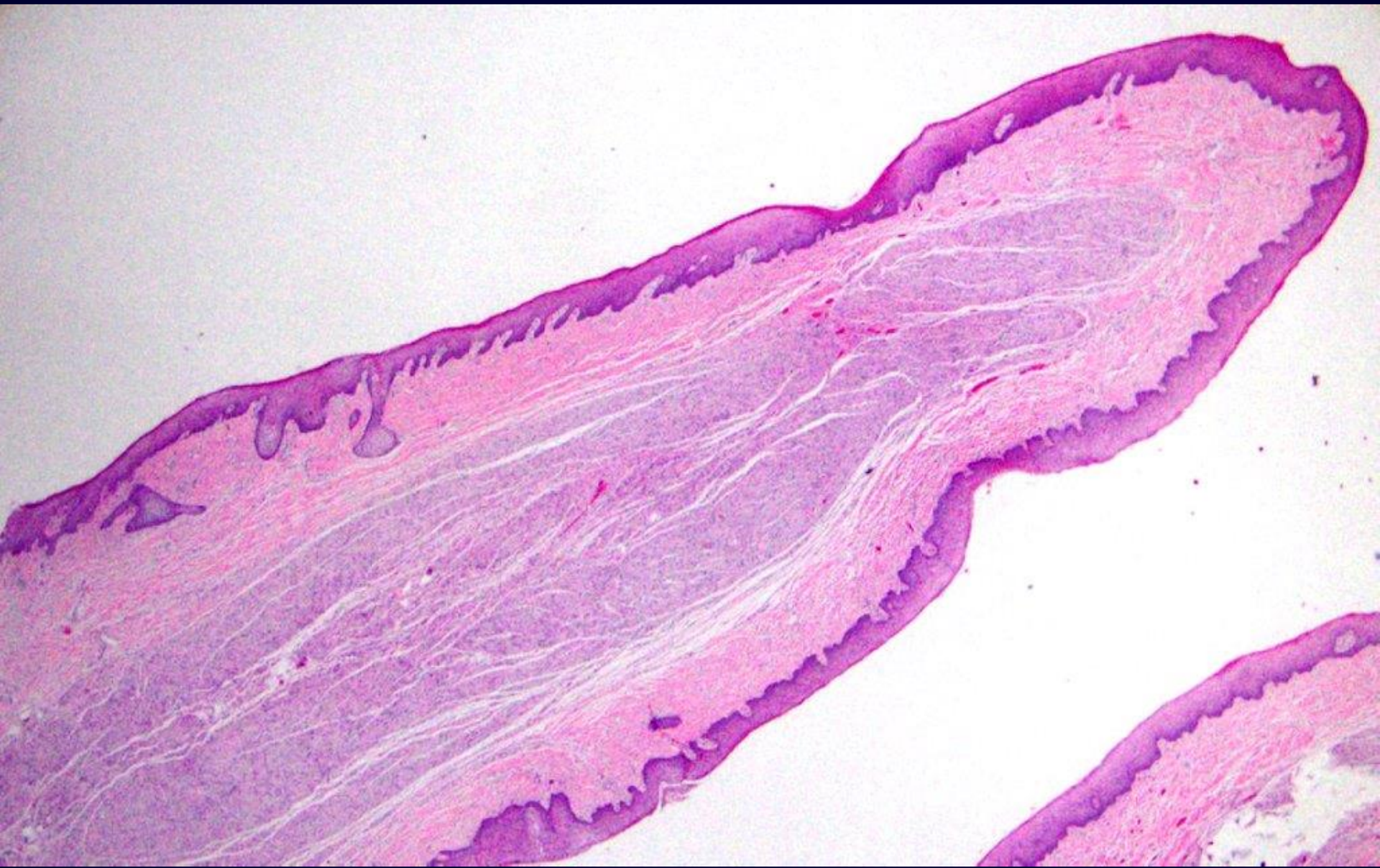


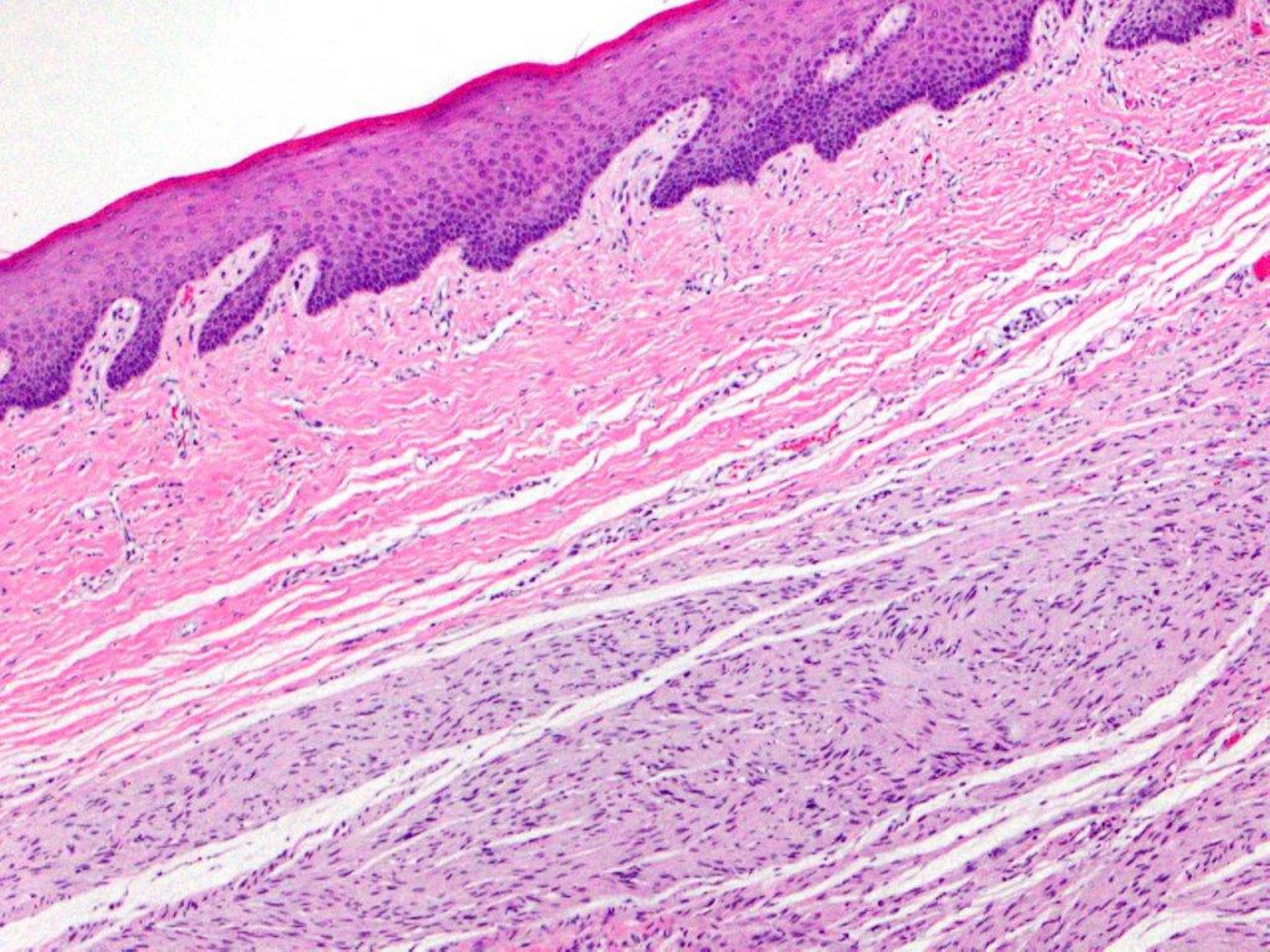


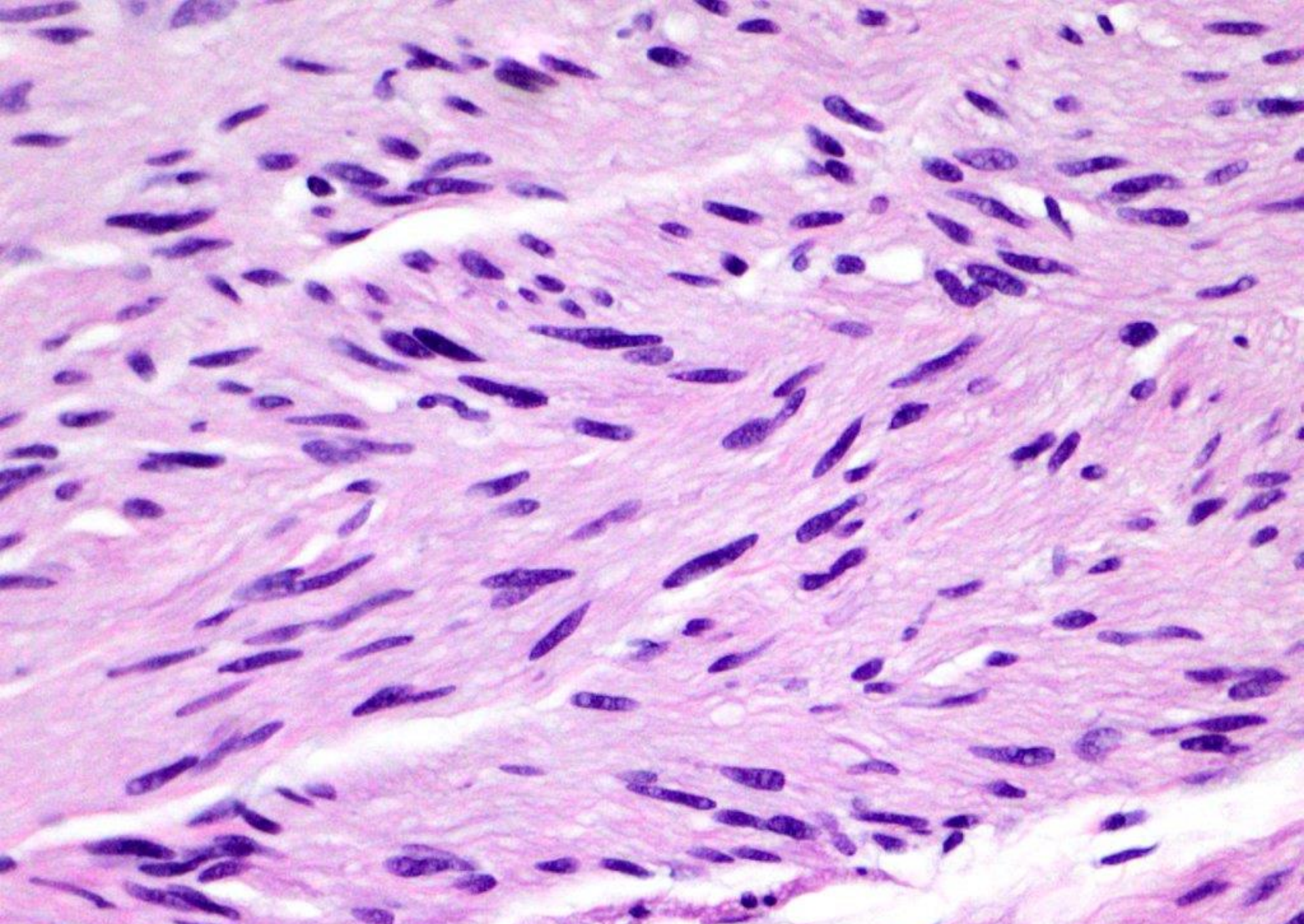




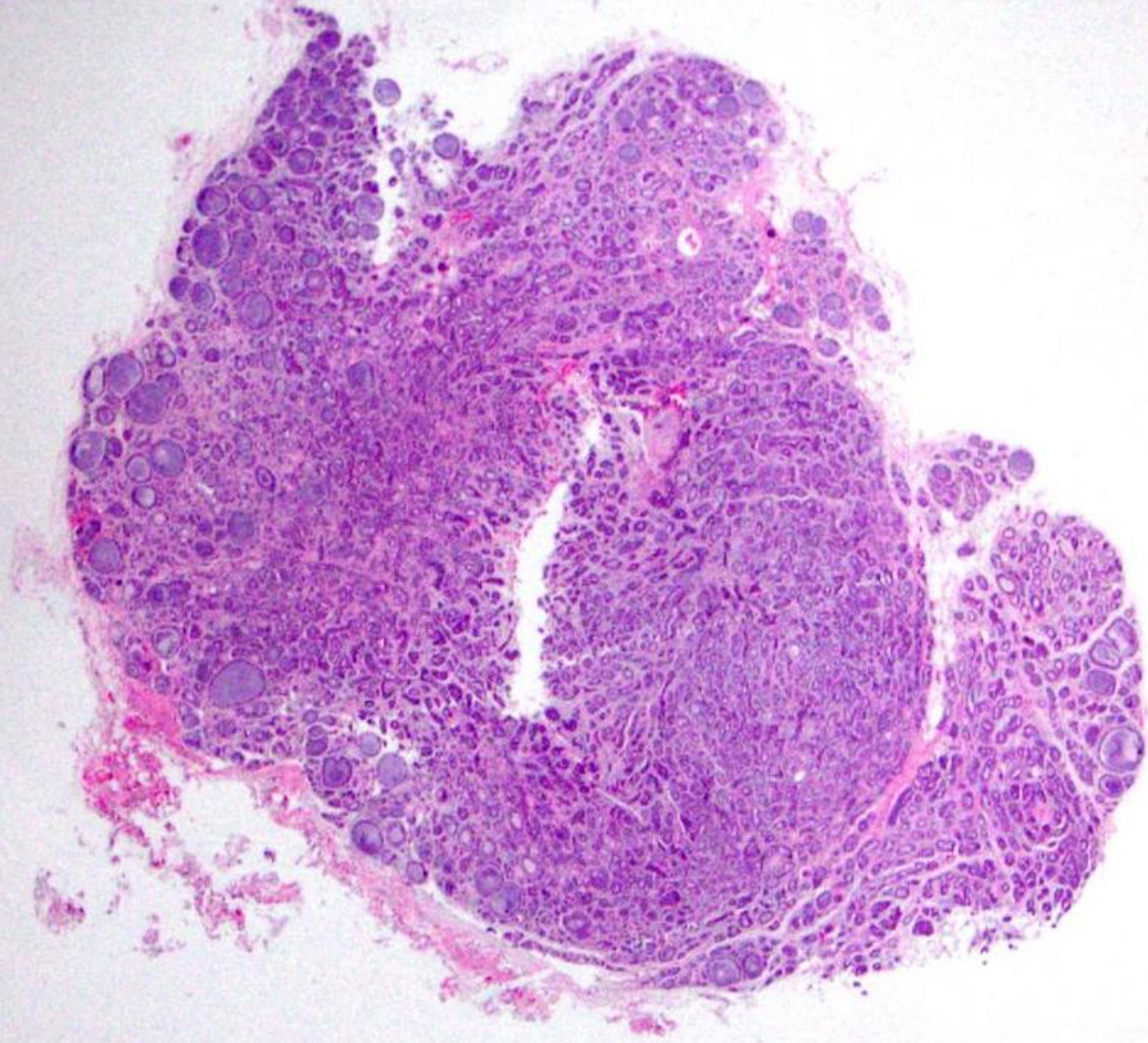
renal osteodystrophy (patient on dialysis, awaiting kidney transplant)

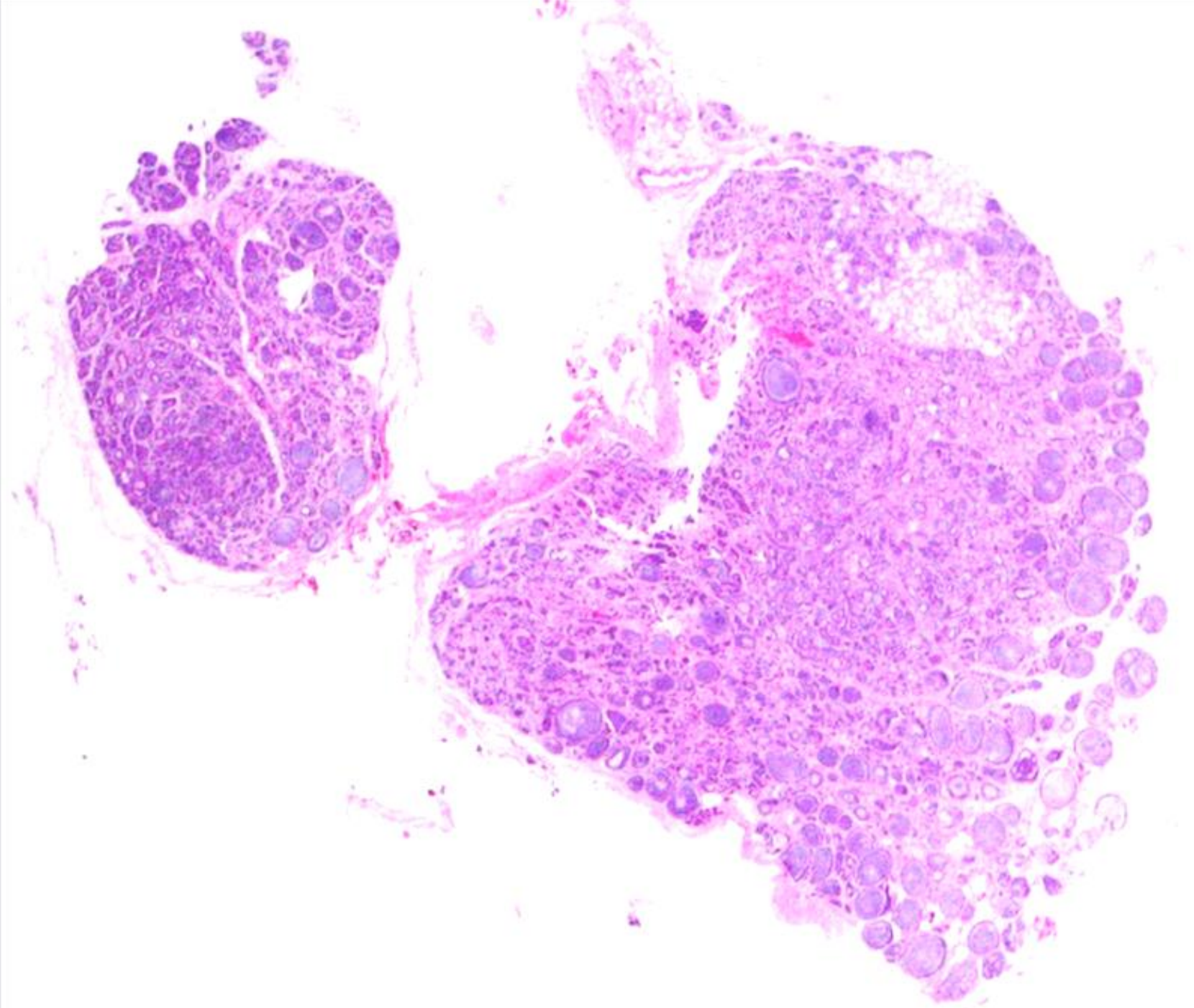


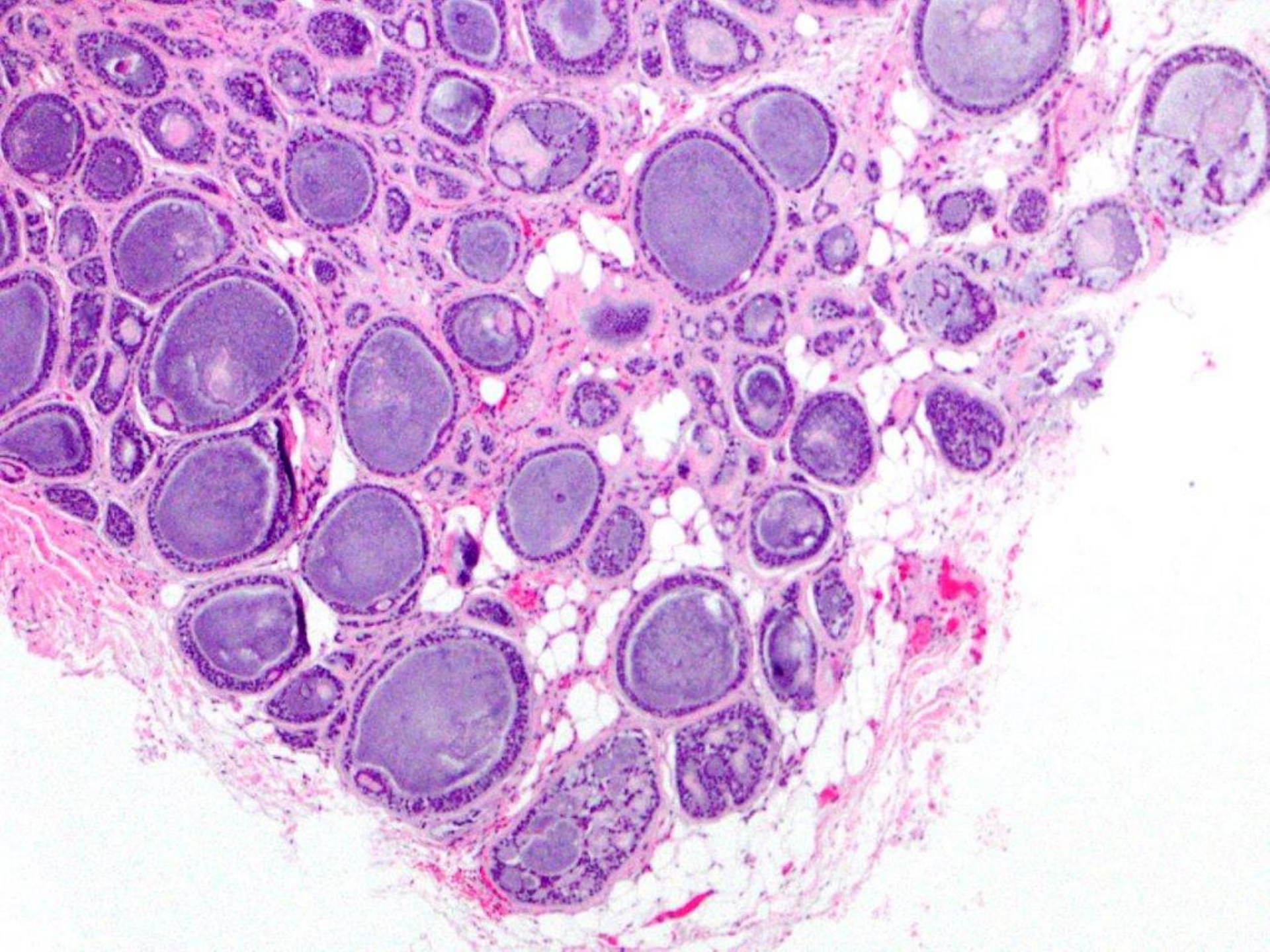


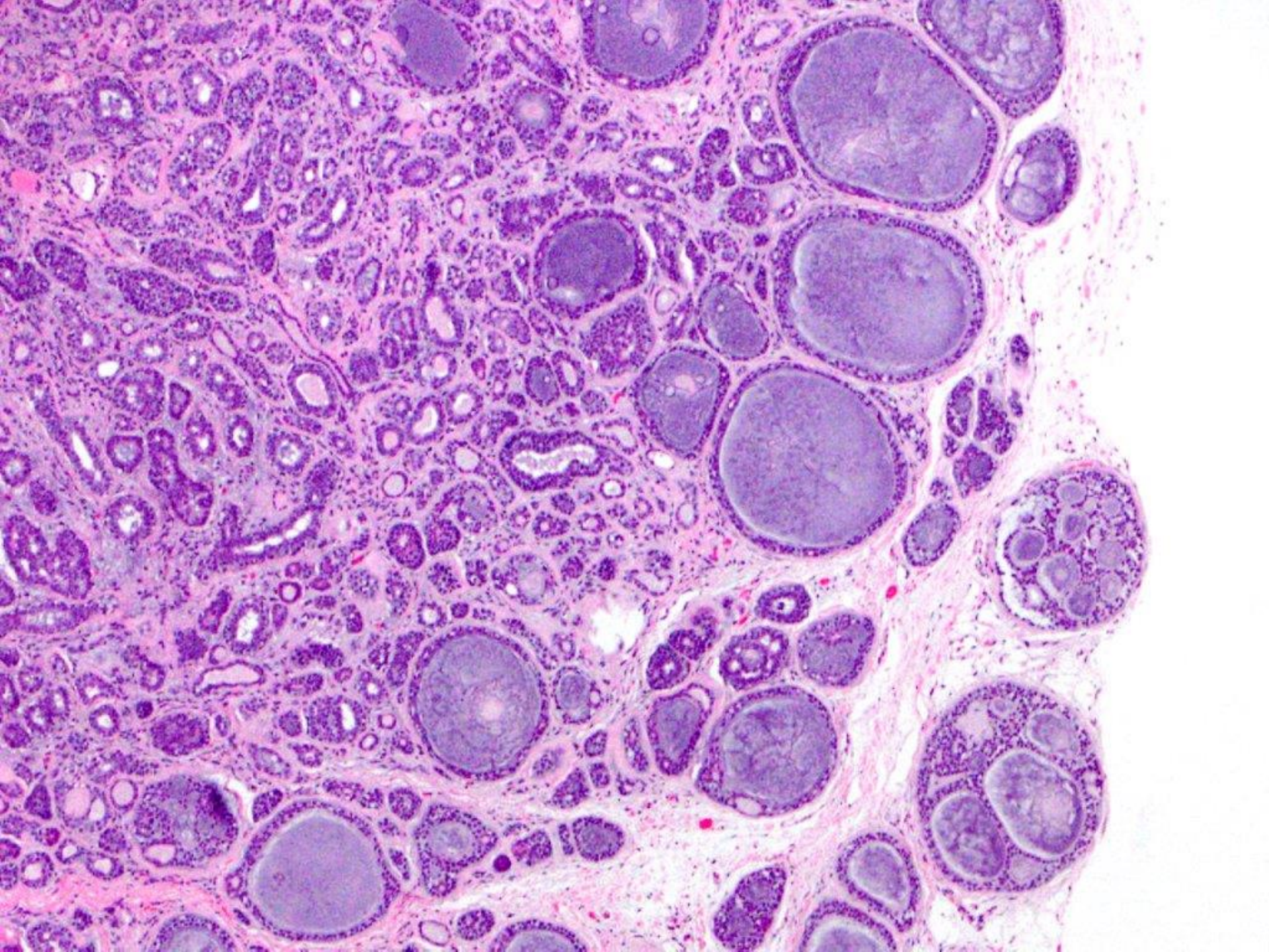


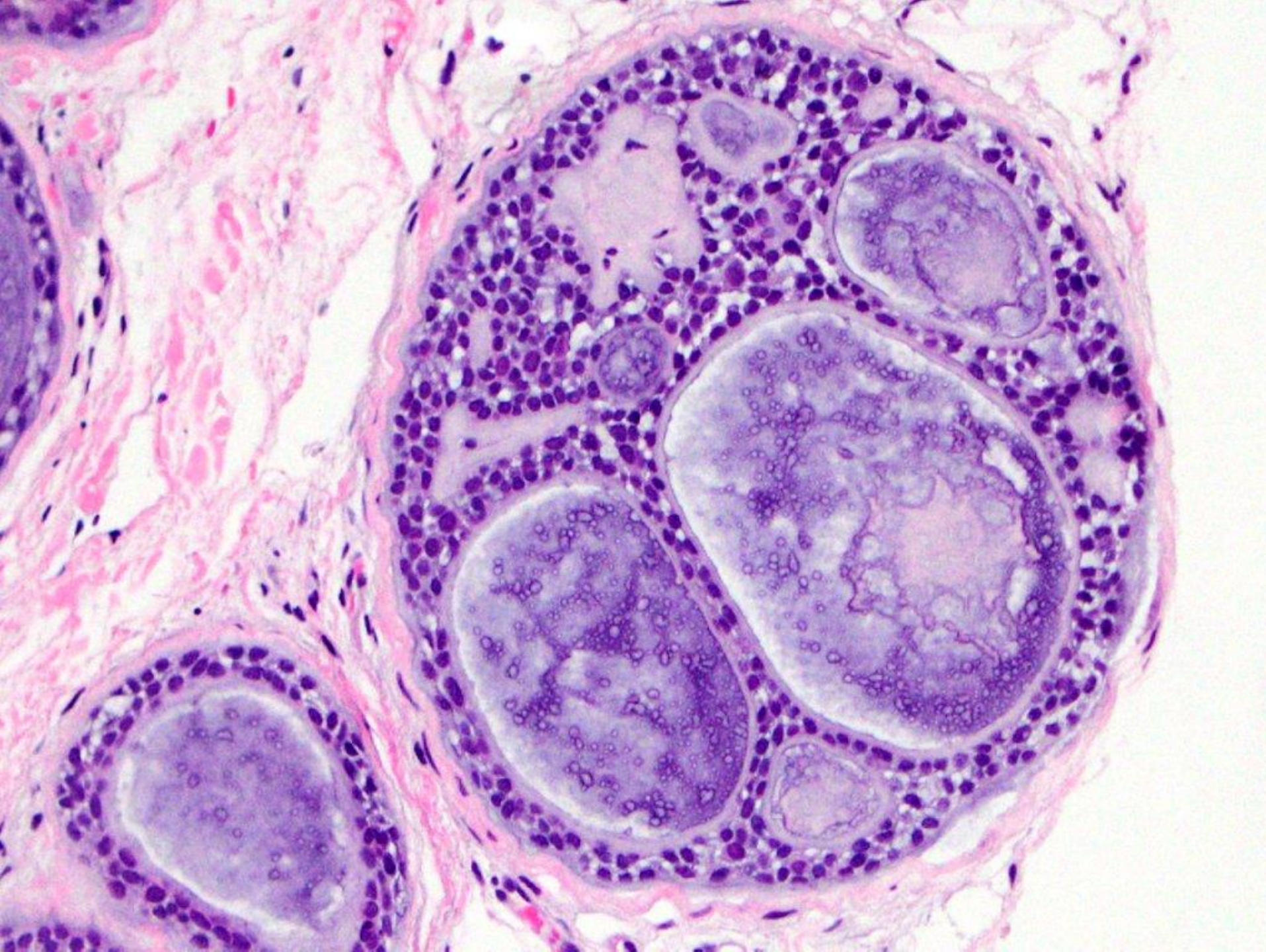
Palisaded encapsulated neuroma (solitary circumscribed neuroma)

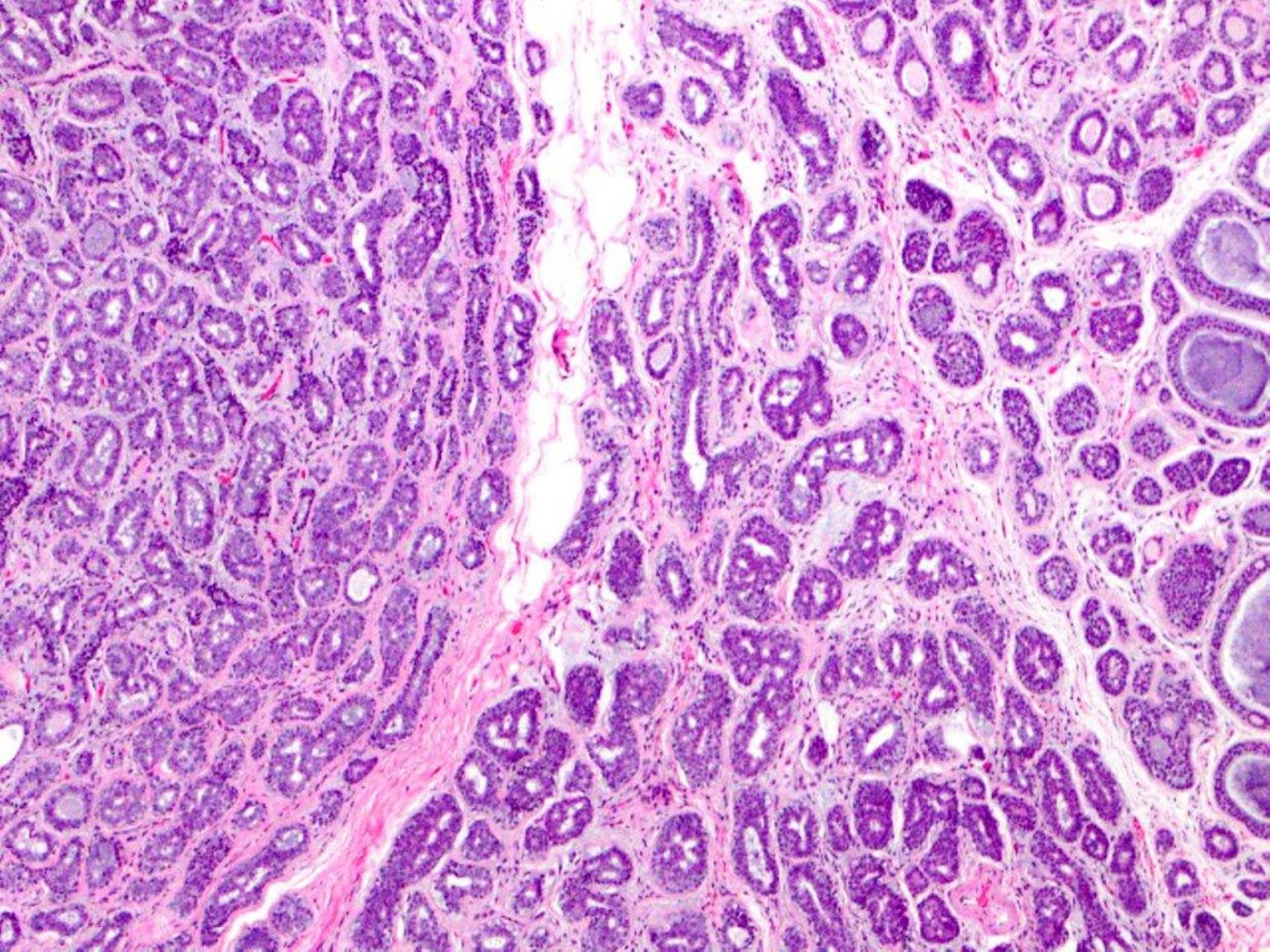


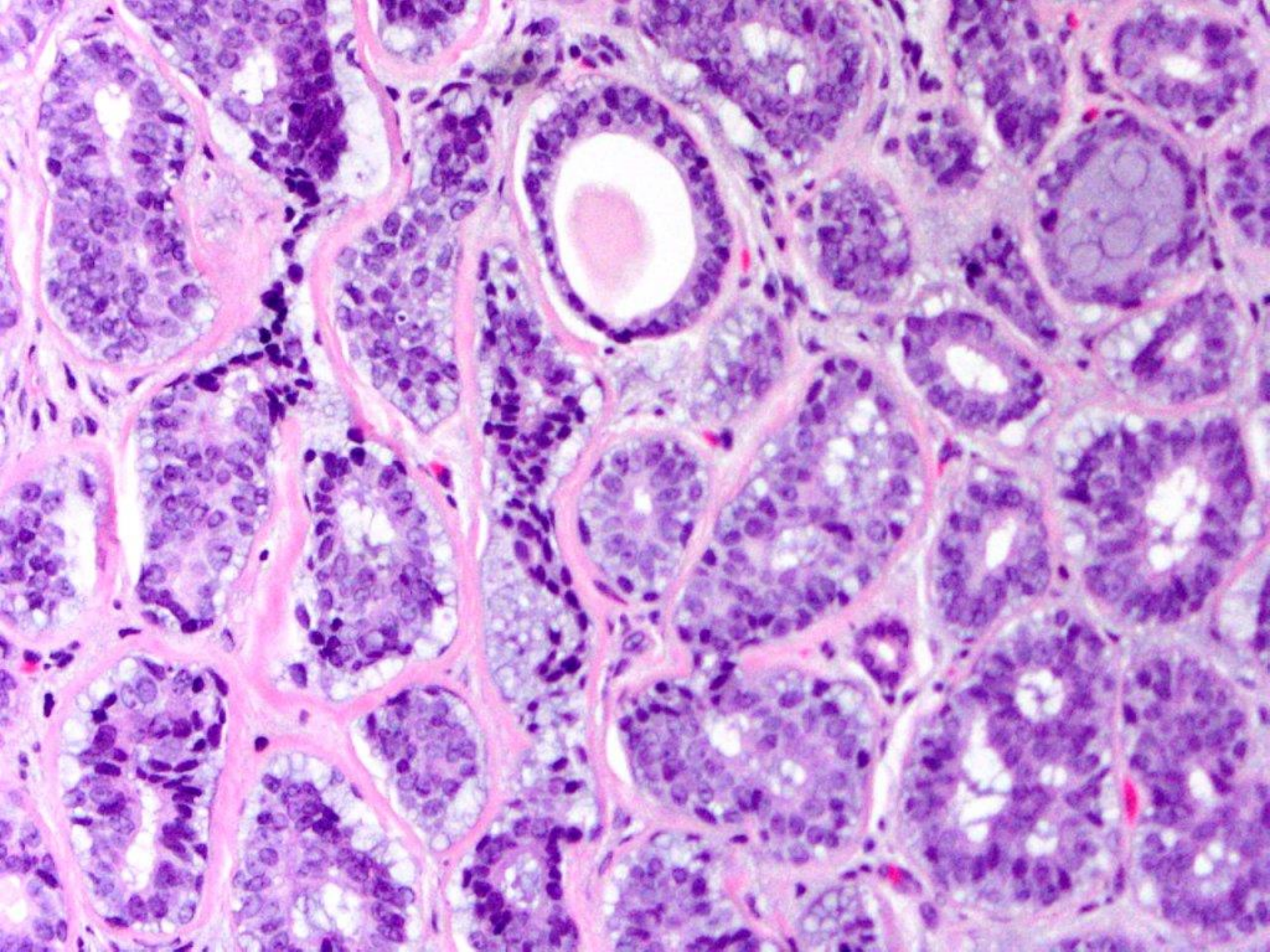


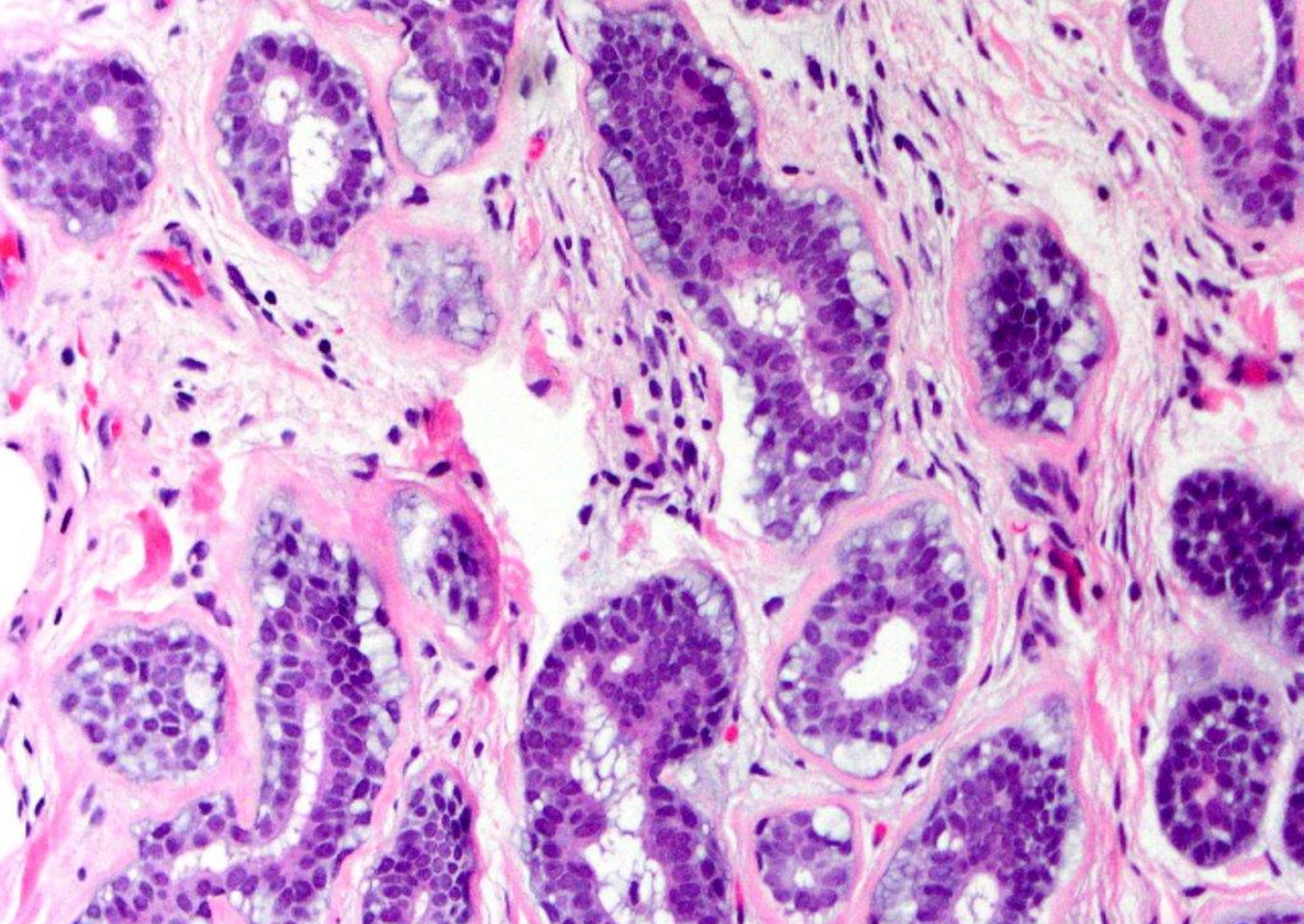




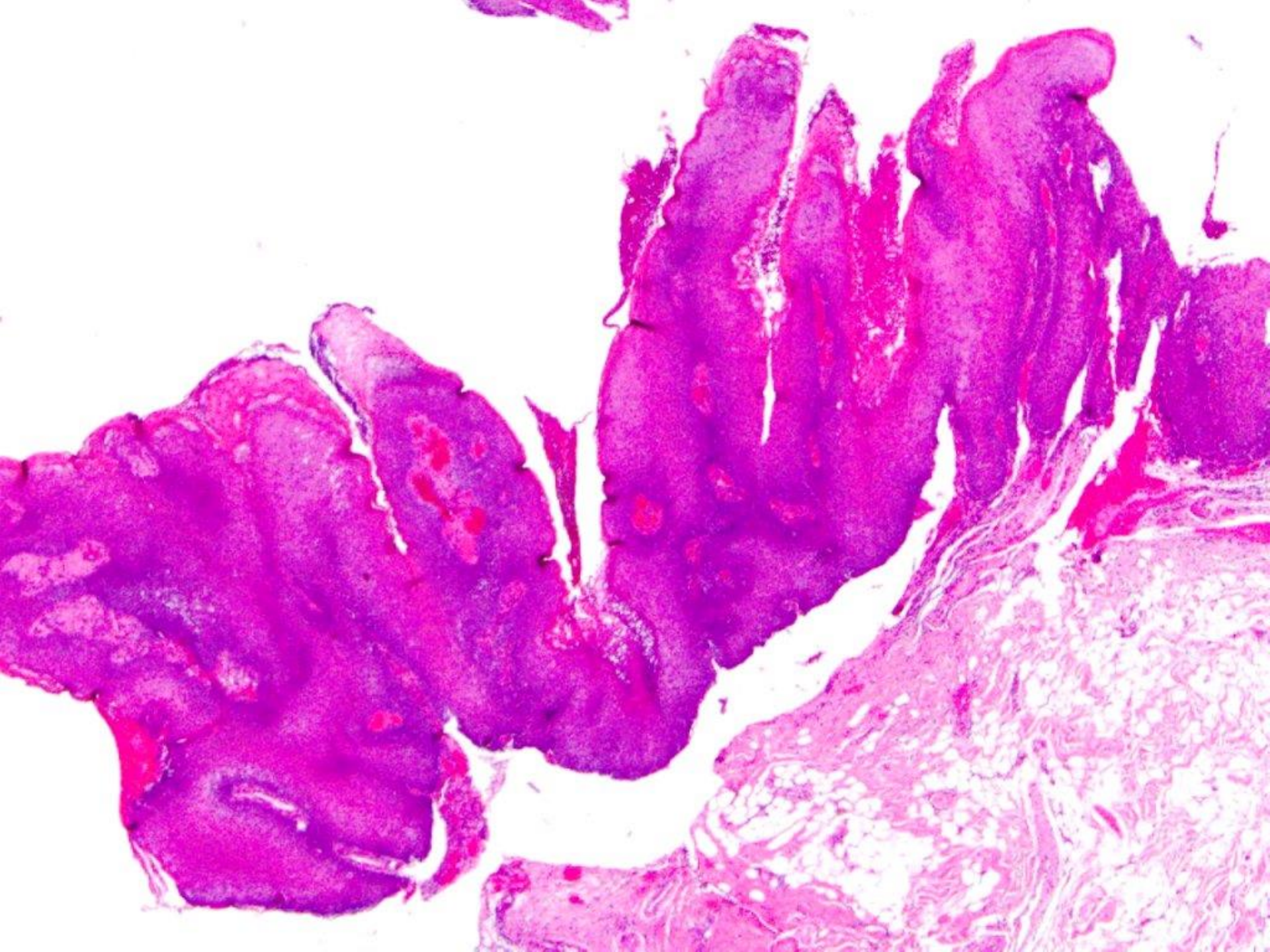


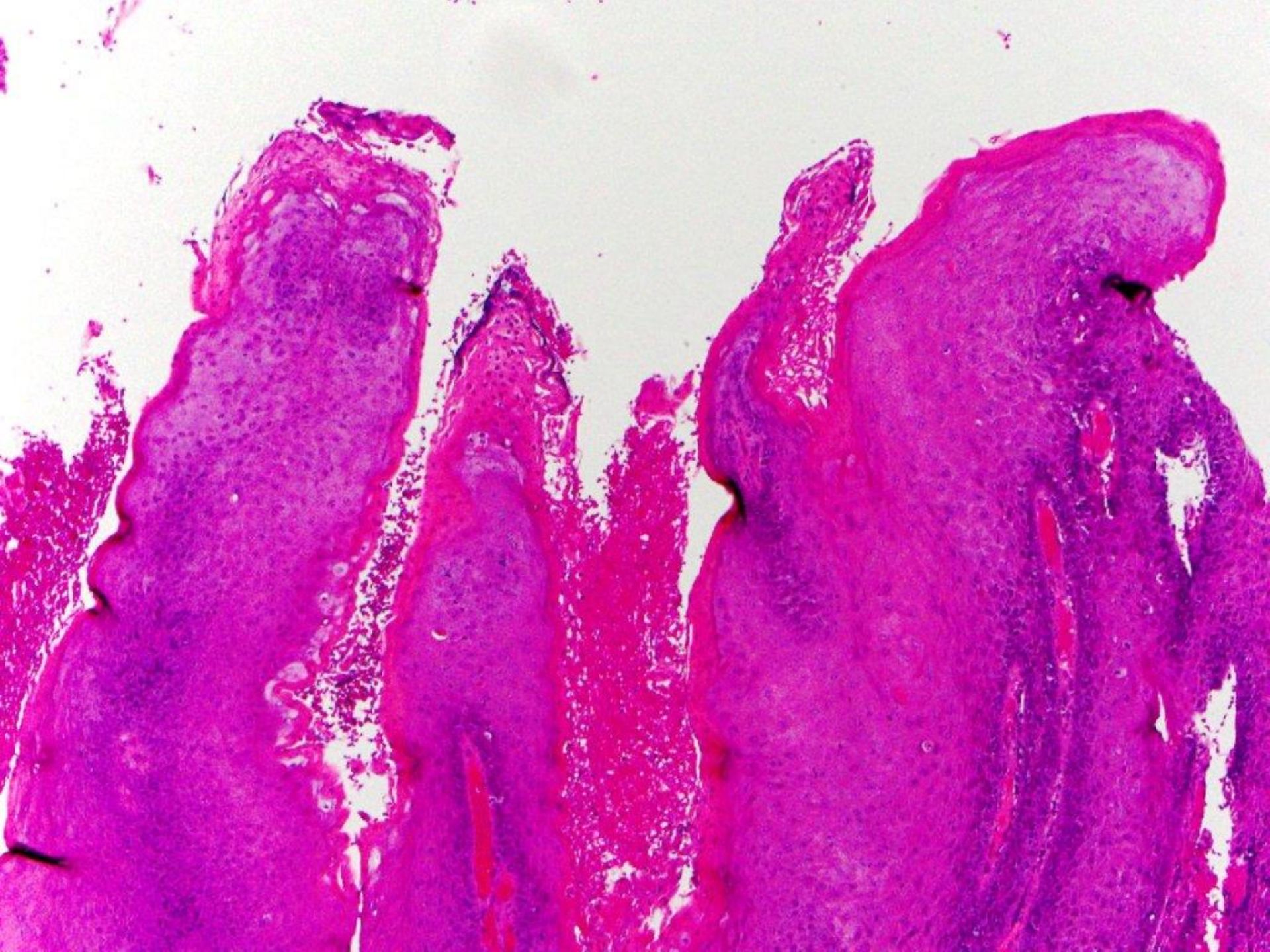


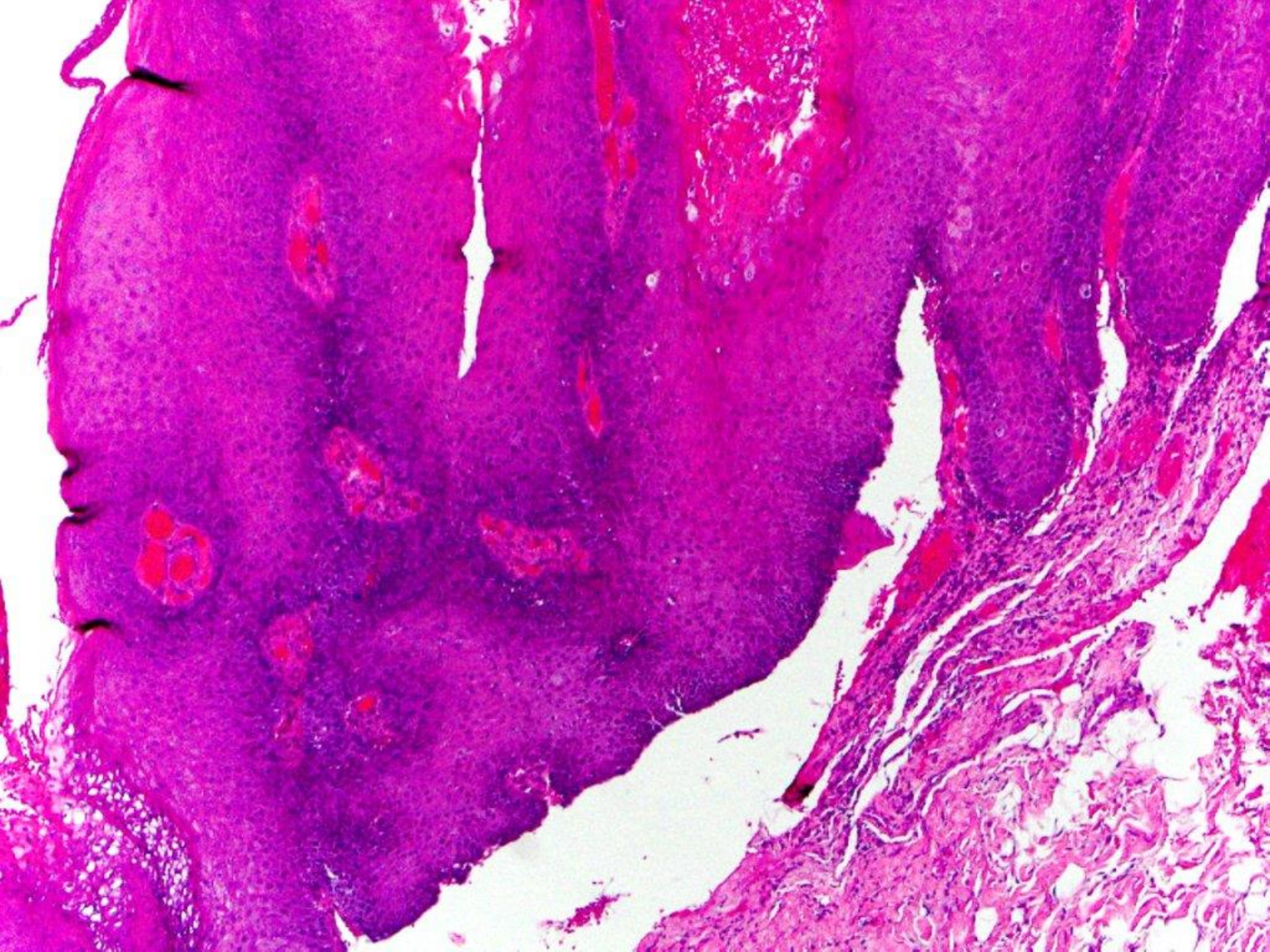


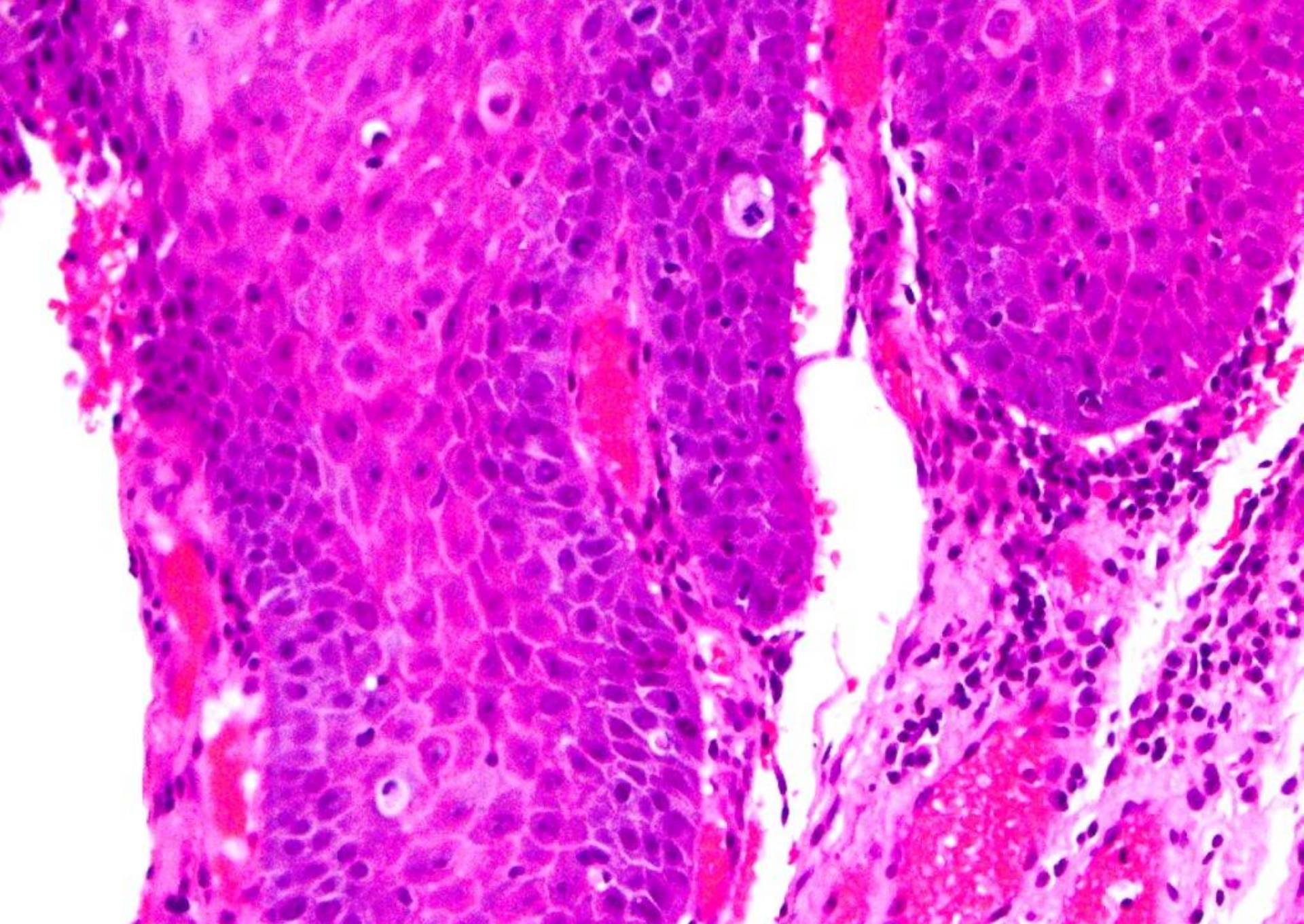


adenoid cystic carcinoma

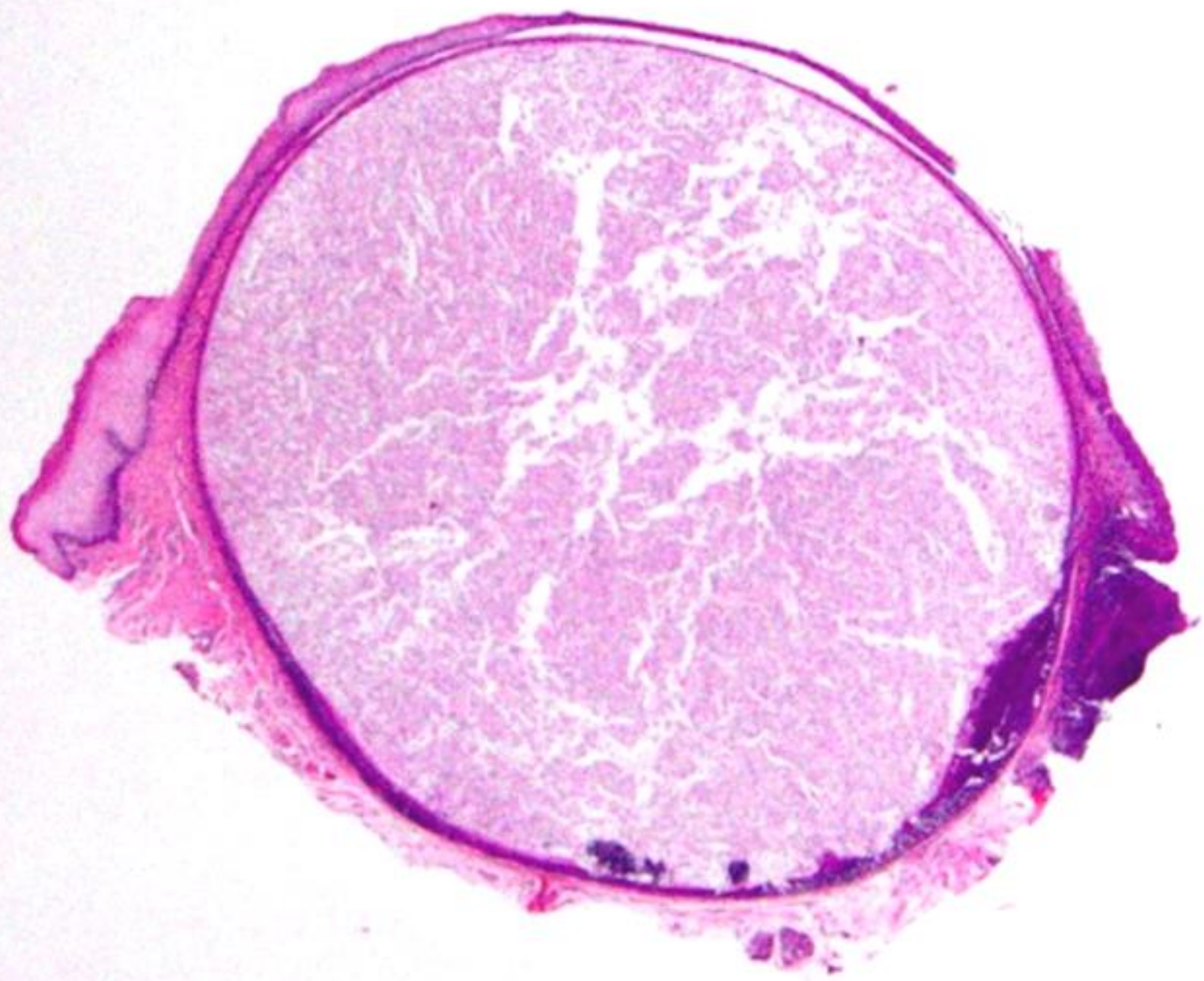


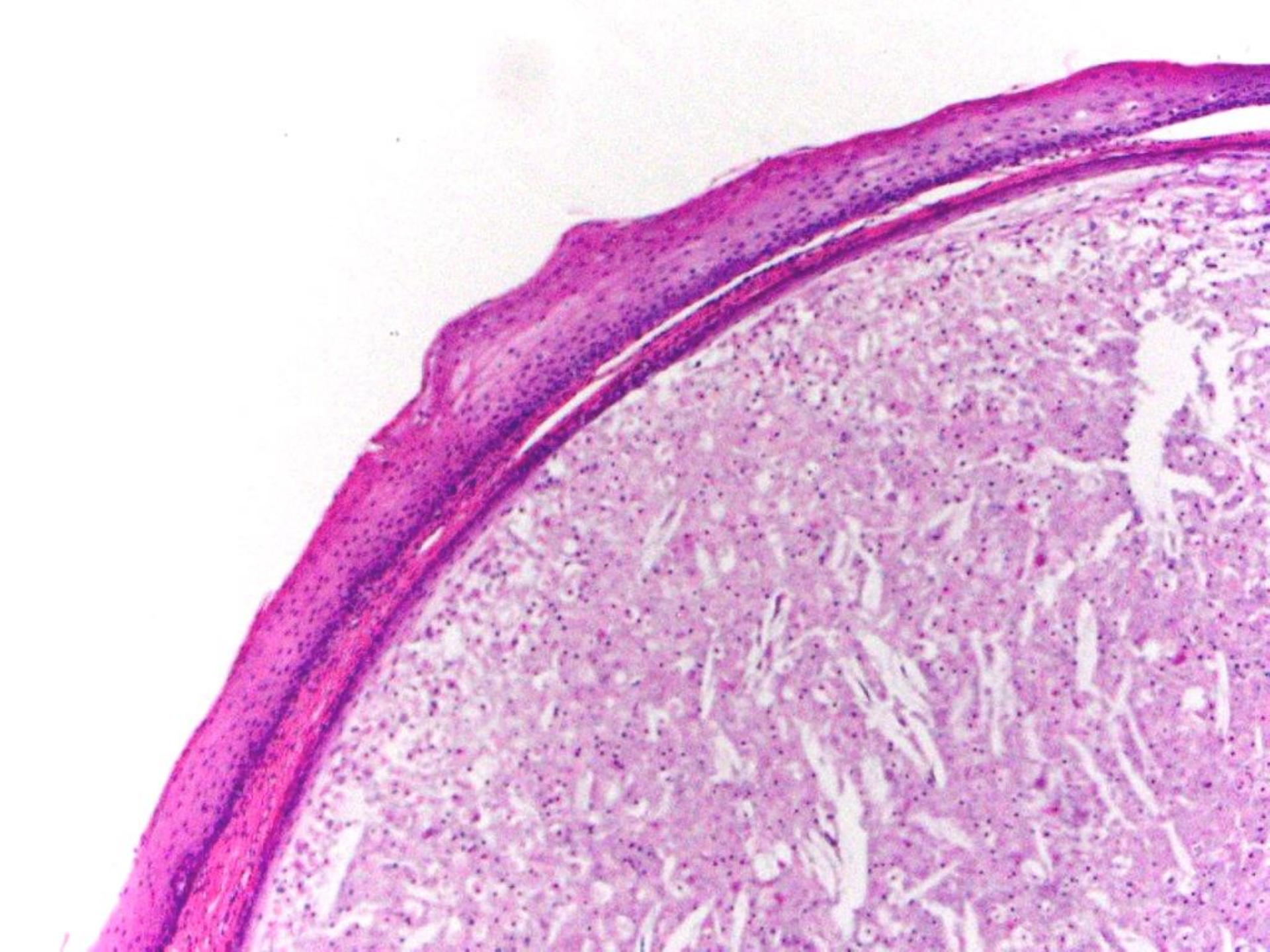


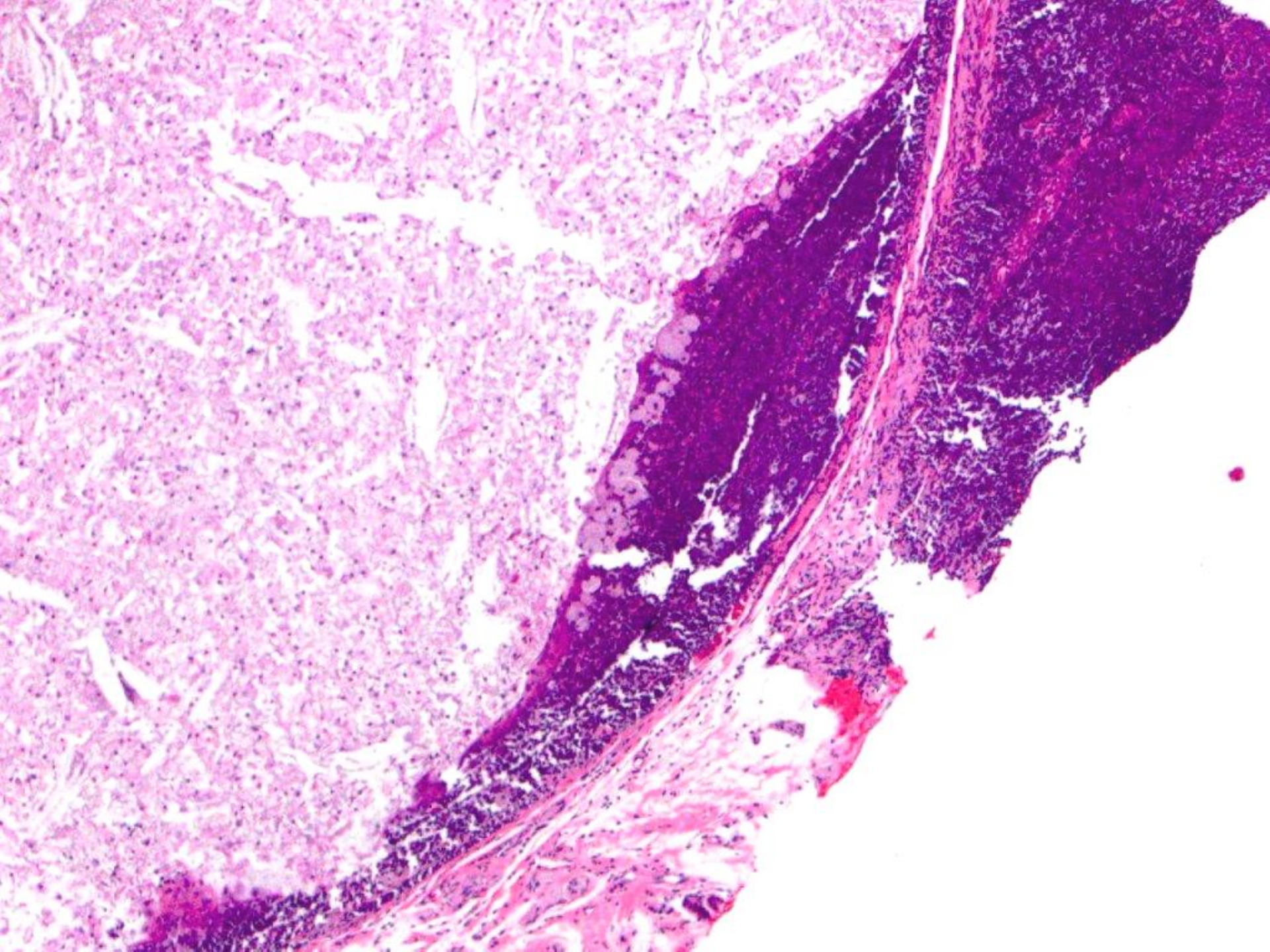


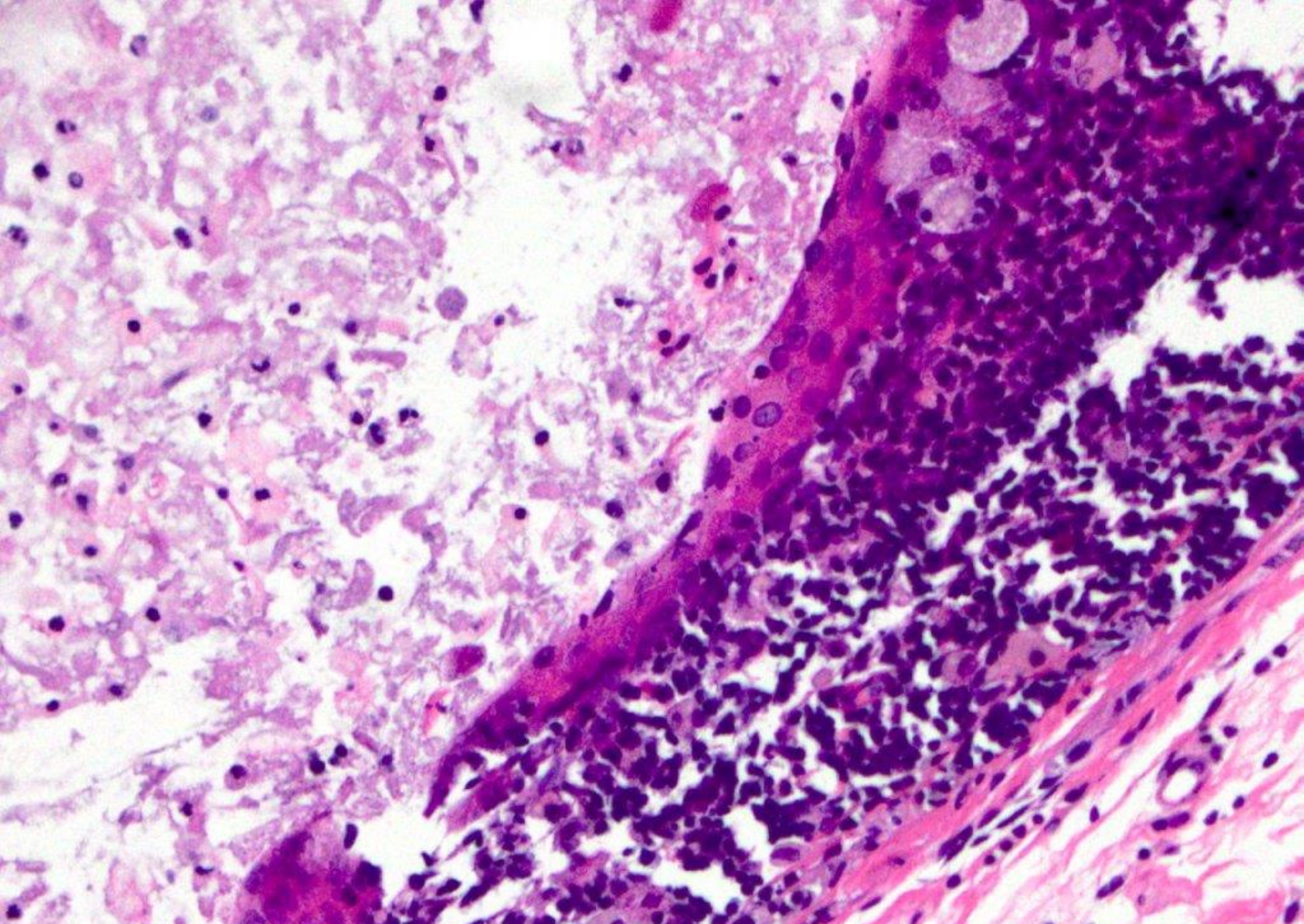


verrucous carcinoma

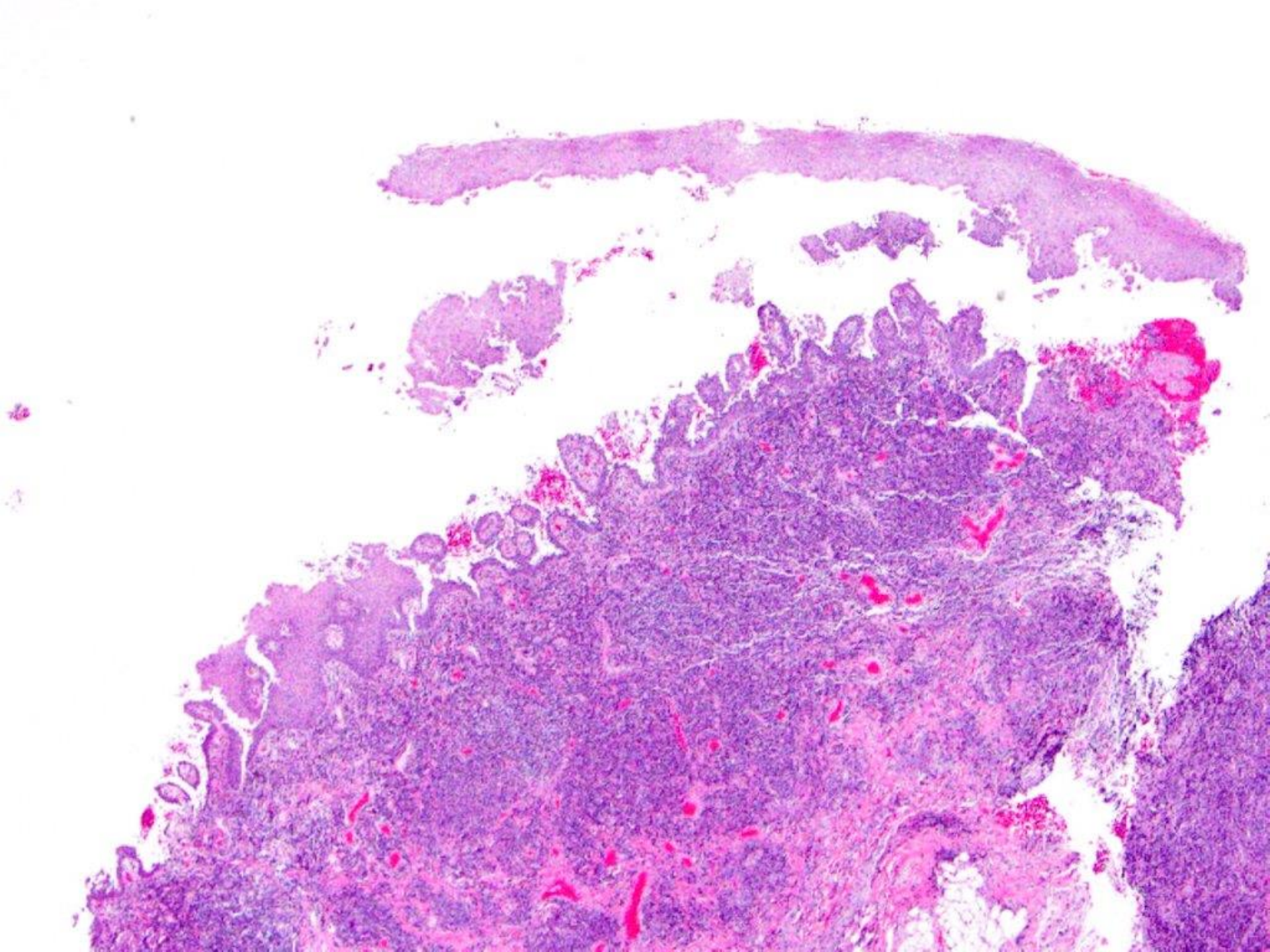


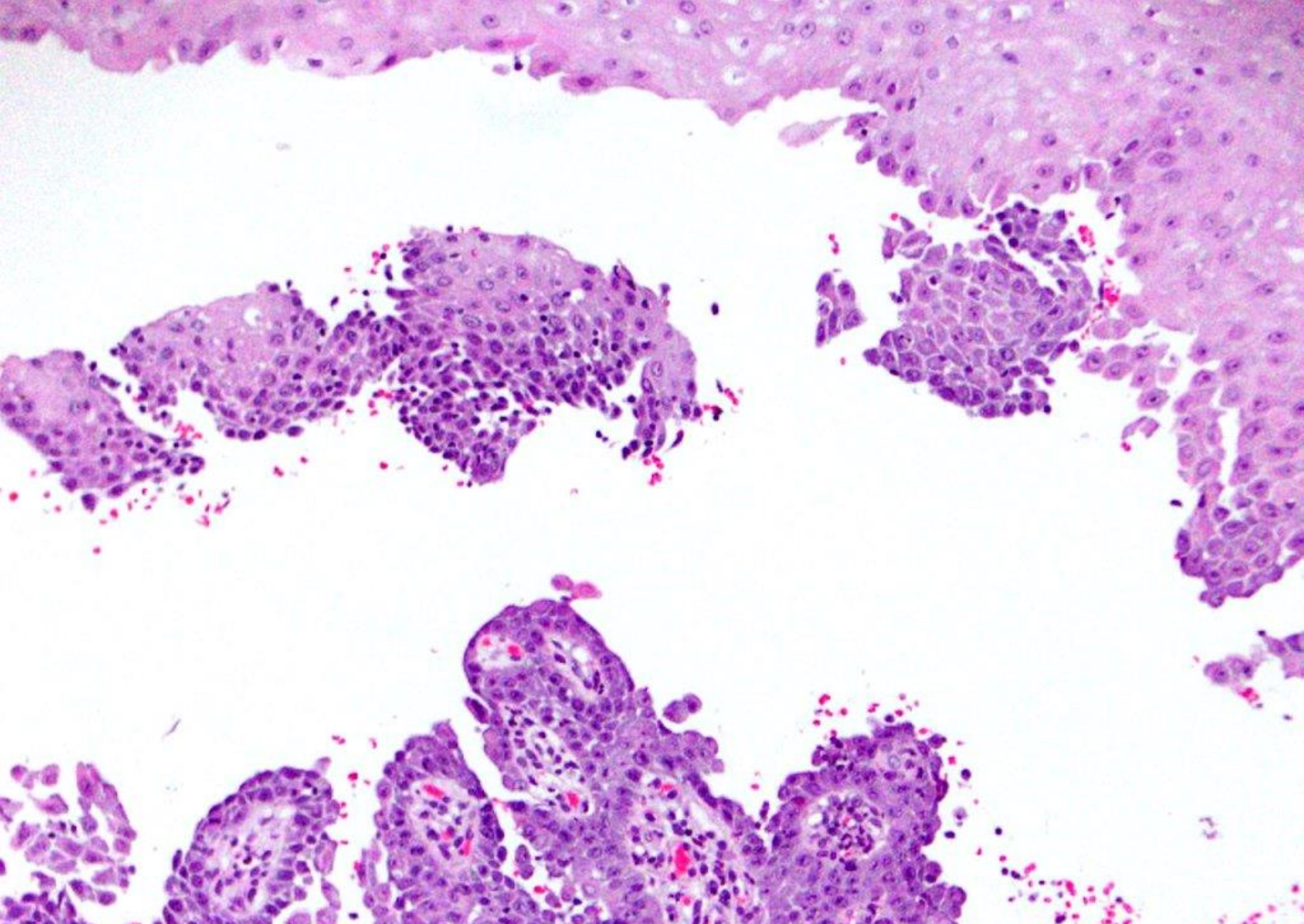




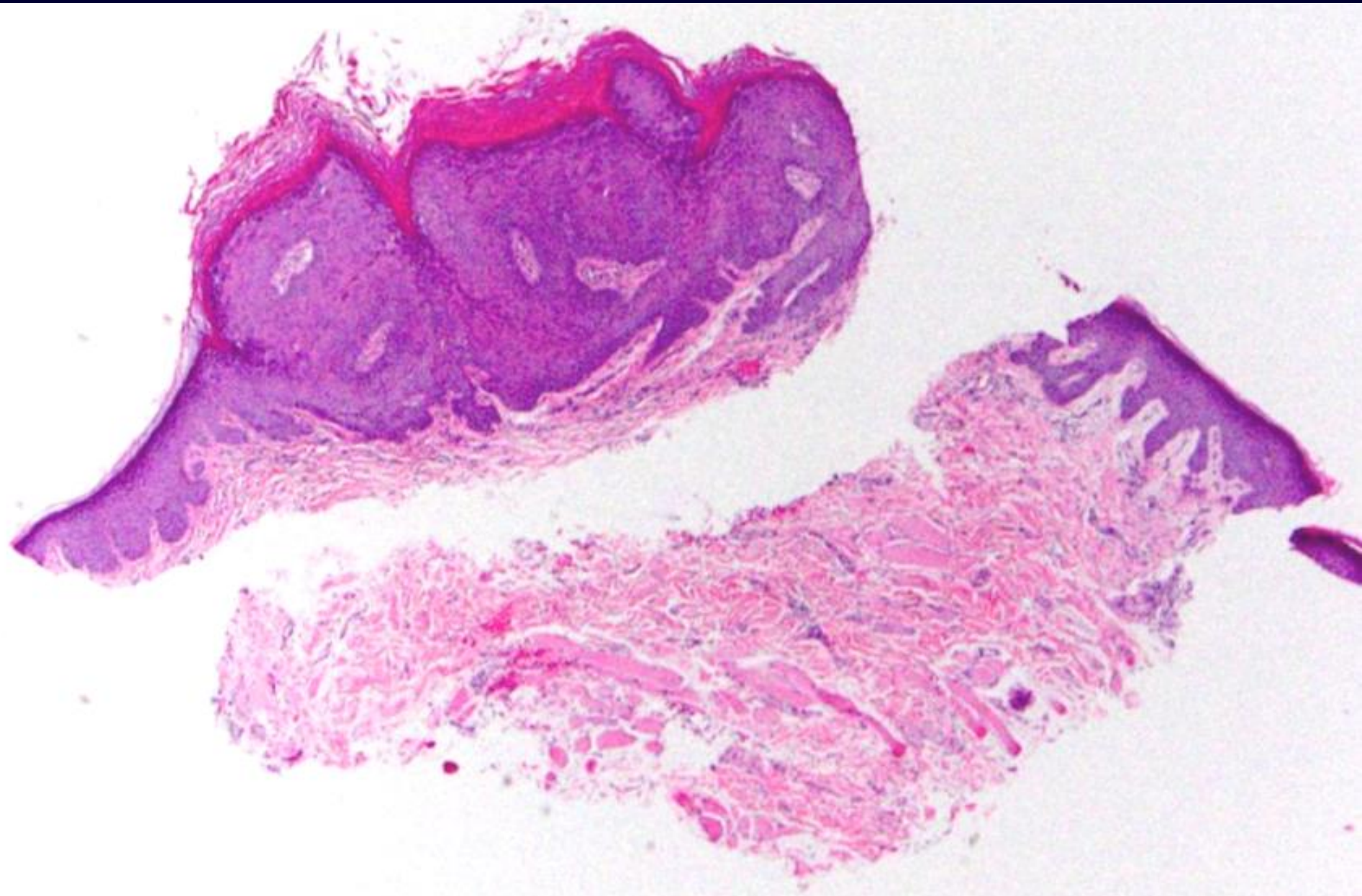


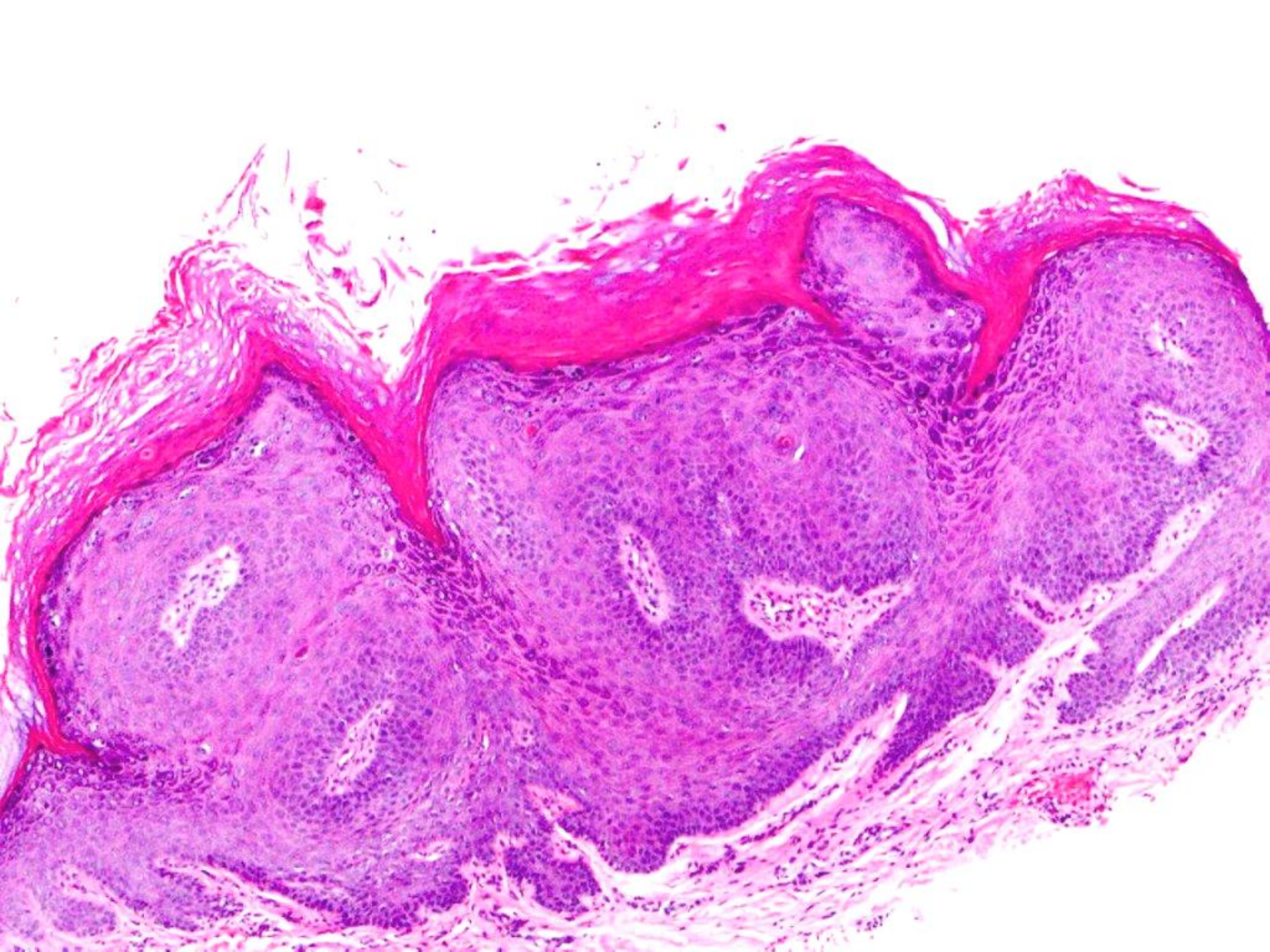
lymphoepithelial cyst

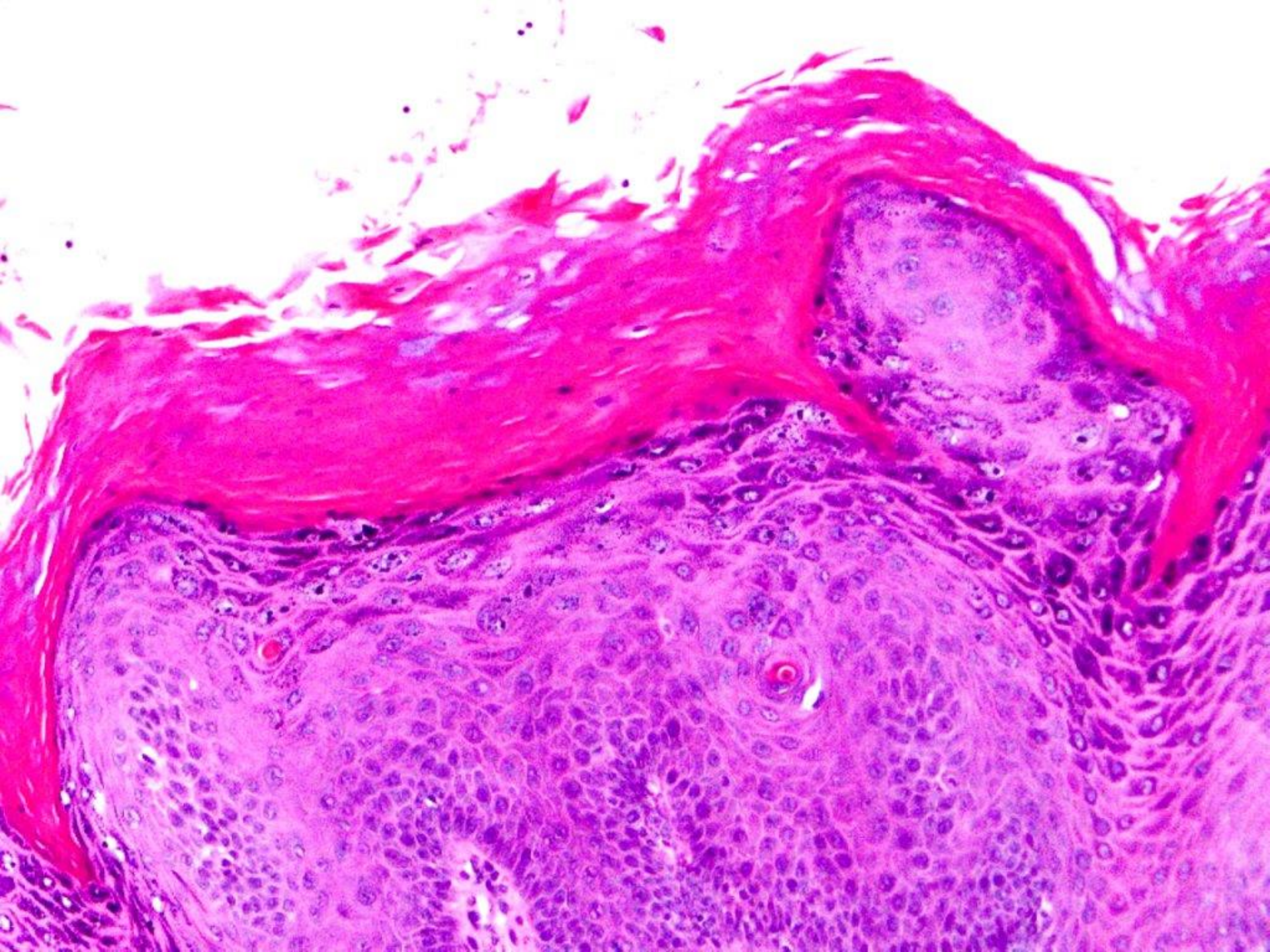


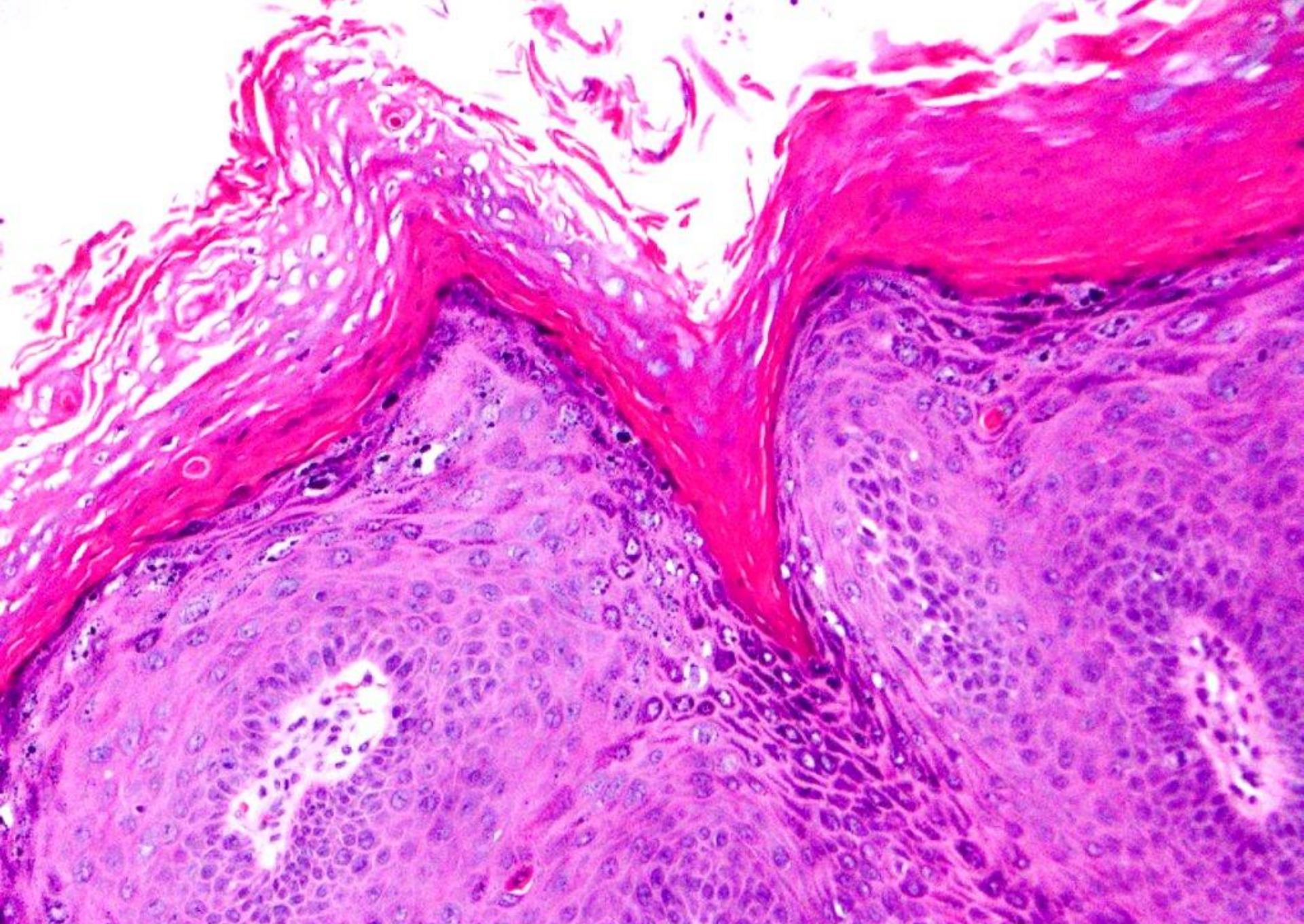


pemphigus vulgaris









verruca vulgaris